

THE
SURGICAL CLINICS
OF
NORTH AMERICA


OCTOBER, 1924
VOLUME 4 — NUMBER 5
PORTLAND—SEATTLE NUMBER

PHILADELPHIA AND LONDON
W. B. SAUNDERS COMPANY

COPYRIGHT, 1924, W. B. SAUNDERS COMPANY. ALL RIGHTS RESERVED.
PUBLISHED BI-MONTHLY (SIX NUMBERS A YEAR), BY W. B. SAUNDERS COMPANY, WEST WASHINGTON
SQUARE, PHILADELPHIA
MADE IN U. S. A.

CONTRIBUTORS TO THIS NUMBER

- JAMES B EAGLESON, M. D.**, Consulting Surgeon, Children's Orthopedic Hospital; Attending Surgeon, Minor and Seattle General Hospitals, Attending Surgeon, U. S. Veterans Bureau, Seattle, Washington
- J EARL ELSE, M. D.**, Chairman of Executive Committee, Department of Surgery, University of Oregon Medical School, Assistant Professor of Surgery, University of Oregon Medical School, Attending Surgeon, Emanuel and Multnomah County Hospitals.
- W B HOLDEN, M. D.**, Clinician in Surgery, University of Oregon Medical School; Attending Surgeon, Portland Sanitarium, and Multnomah County Hospital.
- GEORGE M HORTON, M. D.**, Chief of Surgical Staff, Providence Hospital, Consulting Surgeon, City and County Hospitals, Surgeon, Children's Orthopedic Hospital, Seattle, Washington.
- EVERETT O. JONES, M. D.**, Surgeon, Swedish Hospital, Seattle, Washington.
- THOMAS M JOYCE, M. D.**, Clinician in Surgery, University of Oregon Medical School; Attending Surgeon, St. Vincent's Hospital.
- OTIS FLOYD LAMSON, M. D.**, Consulting Surgeon, Swedish Hospital, Chief Surgeon, Shelton General Hospital, Seattle, Washington.
- J. TATE MASON, M. D.**, Surgeon, Virginia Mason Hospital, Seattle, Washington.
- KARL P. MORAN, M. D.**, Clinician in Surgery, University of Oregon Medical School.
- ALEXANDER HAMILTON PEACOCK, M. D.**, Attending Urologist, U. S. Veterans Bureau; Urologist, Department of Labor and Industries, State of Washington; Attending Urologist, Children's Orthopedic, Seattle City, King County and Snoqualmie Falls Hospitals.
- A. E. ROCKEY, M. D.**, Clinician in Surgery, University of Oregon Medical School; Attending Surgeon, Good Samaritan Hospital
- CASPAR W SHARPLES, M. D.**, Chief of Surgical Staff, Children's Orthopedic Hospital, Chief of Surgical Staff, Seattle General Hospital
- GEORGE W SWIFT, Ph.G., M. D.**, Chief Surgeon, Brain Surgery, Children's Orthopedic Hospital, Attending Surgeon, Seattle General Hospital, Attending Surgeon, Minor and Providence Hospitals, Attending Specialist, Brain Surgery, U. S. Veterans Bureau, Seattle, Washington



CONTENTS

	PAGE
Clinic of Dr J. Tate Mason, <i>Virginia Mason Hospital, Seattle, Washington</i>	1095
.	1105
.	1121
Clinic of Dr Alexander H. Peacock, <i>Minor Private, Virginia Mason and Providence Hospitals Seattle, Washington</i>	
PROSTATECTOMY IN THE ADVANCED YEARS FACTORS IN DETERMINING UPON OPERATION GETTING THE PATIENT IN CONDITION TO SURVIVE THE OPERATION SOME POINTS OF TECHNIC	1125
HYDROPYLONEPHROSIS DIFFERENTIAL DIAGNOSIS LUMBAR EXTRAPERITONEAL NEPHRECTOMY	1133
ADENOPHYEOMA OF THE PROSTATE, WITH PRISMATIC VESICLE CALCULI	1141
DIVER TICULUM OF THE URETHRA CONTAINING A LARGE CALCULUS FREQUENCY OF DIVER TICULI IN THE PROSTATIC URETHRA TENDENCY TOWARD CALCULUS FORMATION IN THE PRESENCE OF STAPHYLOCOCCUS ALBUS DIAGNOSIS AND OPERATION	1149
Clinic of Dr J. Earl Eise, <i>University of Oregon Medical School</i>	
ATYPICAL TOXIC GOITER	1157
Clinic of Dr Everett O. Jones, <i>Swedish Hospital, Seattle, Washington</i>	
PERSISTENT THYROGLOSSAL DUCT	1183
THE USE OF INTRAVENOUS INJECTIONS OF GLUCOSE AND INSULIN IN CERTAIN POST-OPERATIVE EMERGENCIES	1197
Clinic of Dr A. E. Rockey, <i>Good Samaritan Hospital, Portland, Oregon</i>	
APPENDICITIS	1205
Clinic of Dr. Otis Floyd Lamson, <i>Swedish Hospital, Seattle, Washington</i>	
ADHESIONS OF THE UPPER ABDOMEN	1227
CHRONIC PERFORATING DUODENAL ULCER WITH TUMOR FORMATION	1237
Clinic of Drs W. B. Holden and Karl P. Mowbr, <i>University of Oregon Medical School</i>	
MULTIPLE ABSCESSES OF THE LIVER TREATED INTRAVENOUSLY WITH MERCUROCHROME—COMPLETE RECOVERY	1241
ACUTE HEMORRHAGIC PANCREATITIS	1247
GENERAL PYEMIA FOLLOWING CURETTAGE FOR ECTOPIC PREGNANCY	1253
Clinic of Dr. Caspar W. Sharples, <i>Children's Orthopedic Hospital, Seattle, Washington</i>	
PHYSICS OF SOME OF THE DEFORMITIES OF RICKETS	1259
Clinic of Dr. George W. Swift, <i>Children's Orthopedic Hospital Seattle, Washington</i>	
VARIATIONS IN CEREBROVENTRICULAR SIZES	1285
Clinic of Dr. George M. Horton, <i>Providence Hospital, Seattle, Washington</i>	
CARCINOMA OF THE RECTUM	1311
Clinic of Dr. Thomas M. Joyce, <i>University of Oregon Medical School</i>	
DIVER TICULITIS OF THE SIGMOID	1319
CHOLANGITIS WITH STONY	1323
CRETINISM AND MULTIPLE ADENOMA OF THE THYROID	1327
CHOLANGITIS AND CHOLECYSTITIS	1333
CARCINOMA OF THE CECUM	1337
Clinic of Dr. James B. Egleson, <i>Seattle General Hospital</i>	
HYPERTROPHIC PYLORIC STENOSIS . . .	1339

THE SURGICAL CLINICS OF NORTH AMERICA

Volume 4

Number 5

CLINIC OF DR. J. TATE MASON

VIRGINIA MASON HOSPITAL, SEATTLE, WASHINGTON

CARCINOMA OF LOWER LIP

THIS patient is presented to the clinic this morning to show the immediate result of operative treatment of his condition, to permit the discussion of prognosis, and to afford an opportunity to urge the use of every available method for the removal or destruction of cancer cells.

There are many theories as to the nature and cause of cancer. We seem little closer to the true cause than in the time of Hippocrates, who first used cautery in burning a carcinoma from the side of the neck. About fifty years ago Paget and Cohnheim advanced the theory that all malignancies came from misplaced embryonal cells (Cohnheim theory). This theory has now been largely discarded, as it has been shown that the mere presence of embryonal cells is not sufficient to account for tumor growth. Furthermore, tumor growths have been observed without the presence of embryonal cells.

Later the studies of Thiersch advanced the belief in cell autonomy. His consideration was of tumors which arise from cells neither originally misplaced nor essentially embryonal. The advocates of this theory maintain that there are certain restraints to growth, such as tissue tension, which normally control the multiplication of cells and, while permitting normal repair, maintain the tissue in a physiologic condition. There are four factors which control the multiplication of cells: First, mechanical pressure of cells on each other; second, nutrition of the

cells, third, the influence of specialized functions, and, fourth, organization

In the district in which I lived as a boy there was a cancer house. It was believed by my people that its occupants would be infected with cancer. This germ theory was at its height about fifteen years ago. Since then it has gradually lost ground, until today few competent observers consider it as a possible explanation of cancer. Carcinoma has also been attributed to parasites from every conceivable source, such as infected plumbing, trees, stagnant pools, and so forth. These fallacies have been outgrown long since. Finally, it is a universal experience that those treating cancer do not become infected, nor do those who live in houses that cancer patients have recently occupied.

During the past few years some suggestive and startling observations have been worked out by Maude Slye in her work on mice. From these experiments it would seem that heredity plays a much more important part than was formerly supposed. The next outstanding factors that we see clinically are trauma and chronic irritation.

It would seem that, in the light of our knowledge of the cause of cancer, most good can be done by prevention. The public should be taught that there is a precancerous stage. Careful histories should be taken, and when we elicit from patients the hereditary tendency, advice should be given that they may be on the alert for suspicious growths, and especially warned against any chronic irritation or mechanical trauma.

It matters little what particular part of the body is affected. Microscopically we always have about the same picture, which is a group of wild cells from previously normal tissue. These wild cells at first are a localized mass of tissue growing only by continuity. Later they begin to give off cells to the lymphatics or vascular system. Just when this occurs we are unable to say. I feel certain that, if the public could be made to understand this one fact in development of cancer, thousands of our people could be saved annually. Another fact not generally known is that cancer is not painful during the early stage of gradual growth into the tissues.

The treatment of the patient with cancer of the lip, whom I present to you this morning, will be that which all of our cases with these malignant growths are receiving. First, prior to the operation a course of radiation by x-ray or radium is given; second, the growth, with all the lymphatic nodes of the region, is removed by sharp knife dissection; third, we try to destroy the lymphatic channels and any cancer tissue which may have been left by the application of the actual cautery; and fourth, after all this a further course of radiation is given, with the hope that if any of these wild cells have been left, they will be destroyed.

This man is sixty years of age. Most of his life has been spent in a furnishing goods store. There is no history of cancer in his family. Married thirty-five years. Two healthy children, thirty-one and thirty-three years of age. Has lived moderately; never ill except thirty years ago, when he had a slow fever which lasted two months; does not smoke.

One year ago, without any pain or apparent cause, a small sore began on the lower lip. Except to apply zinc oxid ointment little attention was paid to it. Six months ago he was told by a physician the true nature of his disease. A course of five x-ray treatments was given at three-day intervals. After the third treatment, or on the tenth day following the first exposure, the ulcer practically healed. Six weeks later it had returned almost to its original size, when a second series of x-ray was given, with no apparent effect.

The general physical findings are negative. Just to the right of the middle of the lower lip there is an indurated ulcer, slightly smaller than a split pea. It has the punched-out appearance with the white pearly edges, which is present in epithelioma (Figs. 406 and 407). What x-ray treatment he has had has been of benefit in stimulating the formation of fibrous tissue, and in this way delaying the growth. There are some palpable glands in the upper triangle of the neck on the right side. We believe these are inflammatory, as there has been an attempt lately to cure this diseased area by local treatment.

The lymphatic drainage of the lower lip has been so well

worked out that one knows definitely the lymph-nodes that will be affected when the cells break into the lymphatic stream. It is of the utmost importance that the operator keep in mind the



Fig 406



Fig 407

Figs 406, 407 — Patient before and six weeks after operation

lymphatics of this region in relation to the site of the lesion. The position of the lesion and the area which drains it are noted on the chart. *The tissue removed from this area is most care-*

fully examined by the pathologist. The heat is applied longer here, and later the area is given more radiation than elsewhere.

From the middle of the lower lip lymphatics pass to the submental glands, the more superficial ducts anastomosing freely between the two sides of the neck. There are two nodes on each side, one near the middle line and one near the anterior belly of the digastric, superficial to the mylohyoid muscle. Sometimes a chain of glands is found between the mylohyoid and geniohyoid muscles. Lymphatic drainage from the angles of the mouth

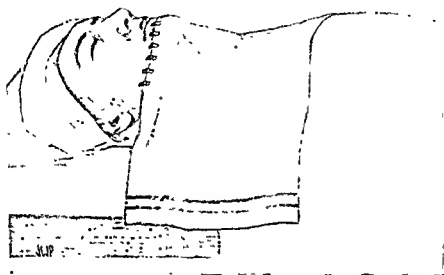


Fig. 408.—Towel held in position with skin clips as used in all neck operations. Towel is turned upward over face. Skin clips attached to towel and face make it impossible for hand of anesthetist to come near wound.

goes to the submaxillary glands on the same side. The glands are found in the triangle formed by the anterior and posterior bellies of the digastric muscle and the ramus of the mandible. One gland is always found between the submaxillary salivary gland and the mandible, necessitating the removal of the salivary glands. The submental and submaxillary triangles drain the entire lower lip, and if the glands are removed early a complete block between the primary focus of the disease and the remainder of the body is established.

Our regular procedure in operating for cancer of the lower

lip is illustrated in Figs 408-412. The incision is made below the ramus of the jaw from one sternomastoid muscle to the other. The second incision is made downward from the symphysis menti to intersect the first incision at its middle. These incisions are made through the skin, not including the platysma. The skin flap of one side is then turned upward (Fig. 409). All the platysma muscles, fascia, fat, and glands are removed from

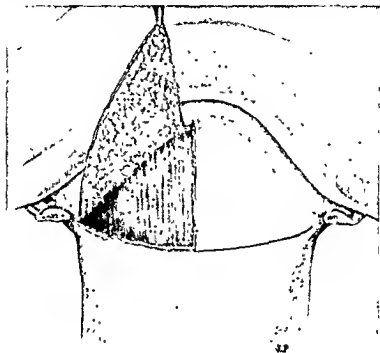


Fig 409 —Skin flap turned back

the submaxillary and submental triangle, beginning the dissection below and removing all the tissue in one mass (Fig 410). With a retractor in the angle of the wound the base of the parotid is exposed, and a small piece removed. No effort is made to save small branches of facial nerve which swing down below the angle of the jaw, and then returns to the side of the face to supply the angles of the mouth.

It is necessary to ligate both facial artery and vein. We have never had a slough from ligation of the vessels going to the face or the flap of muscle and fat which has been removed. The hypoglossal and lingual branches of the facial nerve are exposed and protected. The dissection on one side completed, a gauze sponge saturated with alcohol is placed in the cavity, and the flap pulled down over it, while the dissection of the opposite

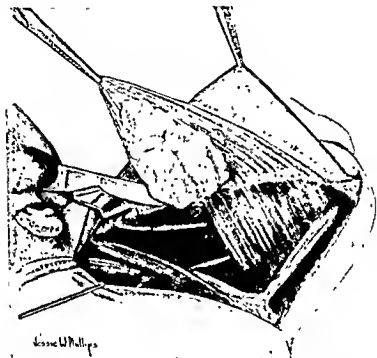


Fig. 410—Platysma, fascia, fat, and glands removed from submaxillary and submental triangles on right side of neck. This same procedure is next carried out on the opposite side.

side is performed in the same way. When the dissection of both sides is completed, wire retractors are placed in the edges of the wound, at both angles of the jaw and the midline (Fig. 411). All oozing is stopped and the entire wound swabbed with alcohol again. The alcohol sponge is followed by dry sponging until the wound is dry. Actual cautery is now applied over the region of the removed lymph-nodes, but not on the under surface of the flap, which sloughs if accidentally burned with the cautery. By placing the forefinger between the end of the cautery and the

nerves they can be pushed to one side and protected. The flaps are turned back into place and skin clips applied, and a small rubber drain placed between every third or fourth clip (Fig 412). This is important, as there is much inflammatory exudate following the cauterization.

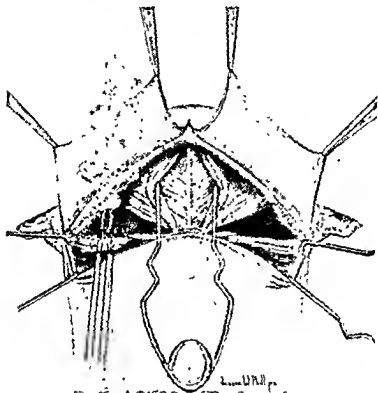


Fig 411 —Dissection of both sides of neck completed. Retractors in place and actual cauterization being applied to right submaxillary triangle

The wound in the neck is carefully protected, and the operation on the lip begun. We shall remove a V-shaped section in this case, including the growth, and a good quarter of an inch on either side of the healthy tissue. This V-shaped incision is sutured together on both sides with horsehair, painted with 50 per cent. tincture of iodine, and left with no dressing.

Results.—The section removed from the lip will be graded

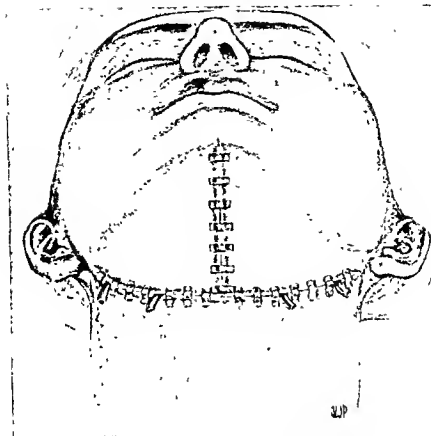


Fig. 412 —Closure Skin clips and drains in place



Fig. 413 —Patient operated upon eight years ago. No recurrence to date

as to malignancy by the pathologist. If he gives a favorable report in regard to appearance of the cells, we will feel that the patient is cured. But if the report comes back that the cells are breaking through in great profusion, etc., the prognosis will be bad. Our most satisfactory results with cancer have been when it was located on the lip. They are usually slow growing, with but small tendency to form metastasis in other parts of the body.

I would like to show you a picture of a man (Fig. 413) who had a much larger growth than this one, who was operated on

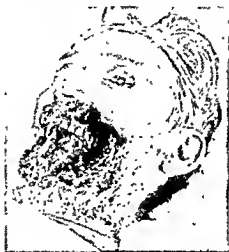

Fig. 414 —Operation refused. Photograph made just before death.

eight years ago with the same technic, except that some plastic work was done at each angle of the mouth to bring it back to normal size. He has developed a partial hemiplegia since then, but there is no evidence of recurrence. I will also show you a picture, taken a few weeks before death, of another man who refused operation (Fig. 414).

FOUR CASES OF EXOPHTHALMIC GOITER. PARTIAL THYROIDECTOMY PERFORMED IN CASES I AND IV

PRESENTATION OF SOME OF THE INTERESTING MEDICAL PHASES OF EXOPHTHALMIC GOITER, BY JOHN M. BLACKFORD, M. D.

General Remarks.—Exophthalmic goiter, with few exceptions, runs a typical course. Had we known in the early years the usual course of the disease, our mortality would have been lower.

The typical case shows a slight thyroid enlargement with mild toxic symptoms during several months. The symptoms gradually increase until about the eighth month, when they become markedly worse. About the ninth month there is an explosion of symptoms commonly known as a crisis. Then there is a period of improvement with fairly constant symptoms. At about the end of the second year a second crisis occurs, never quite so severe, from the standpoint of toxicity, as the first. After this there are ups and downs until after years the toxicity of the goiter wears out, and we have occasionally a cure, but usually a human wreck suffering from cardiac and general degeneration.

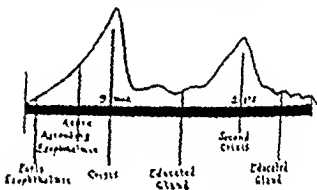
We have for some years endeavored to classify exophthalmic goiter in workable form. Clinically this classification comprises four groups. This was adopted so that internist, surgeon, laryngologist, nurse, and everyone concerned with the case might understand about what was to be expected of a patient in a given group (Fig. 415).

The 4 cases which I shall present are selected, representing one of each of the stages.

The first case is a very early one, at the stage in which diagnosis at times is difficult, because no specific criteria can be set as to when normal function of the gland ends and hyperthyroidism begins. This stage we designate as "early exophthalmic."

The second case is one of pronounced and progressive toxemia. The history of illness is of a few months' duration only. There is much loss of weight, a racing pulse, and the basal metabolic rate is plus 75. This stage is designated as the "acute exophthalmic."

The third case is one in crisis, which means fully developed. Some of these fully developed cases are not so extremely ill others are, and they are characterized by cardiac decompensation, vomiting, acidosis, prostration, delirium, and sometimes death. This syndrome is designated as the "crisis."



Usual course of exophthalmic goiter. The horizontal represents the normal death line.

Fig. 415.

The fourth has been ill for eight years. There is marked exophthalmos, tremor, some bronzing of the skin, basal metabolic rate plus 48. It is with great difficulty that she carries on her work as a school-teacher. Compared to her former self she is a physical wreck. This we have designated as a "late exophthalmic" or "educated gland."

CASE I. EARLY EXOPHTHALMIC GOITER

This patient, Miss G. M., aged twenty-three, consulted me complaining of palpitation of the heart, worse on exertion. The tonsils were well removed at the age of seven years. Tro

years ago she had an operation for appendicitis, with an uneventful recovery. Three months ago she was ill for a few days with a sore throat. Since then she has been unable to work on account of headaches and palpitation. There has been no loss of weight; sleeps poorly, very nervous during the day; appetite excellent. The thyroid gland is about three and one-half times as large as normal. It is symmetrically enlarged. A slight bruit can be heard over each superior thyroid artery.



Fig. 416.—Early exophthalmic goiter six days after operation.

The patient was admitted to the hospital fifteen days ago. The basal metabolic rate was plus 19, with a pulse of 118. Under treatment with Lugol's solution and rest in bed the pulse-rate has dropped to 80 and the basal metabolic rate to plus 11. There is no exophthalmos present, nor has the disease produced any marked changes in the vital organs. The results from a partial thyroidectomy in this case will be practically 100 per cent. perfect. We shall leave about one-eighth of a normal sized gland on each side (Fig. 416).

CASE II. ACUTE ASCENDING EXOPHTHALMIC GOITER

This patient is thirty-three years of age. She has been fleshy for the last twelve years. Her normal weight is 260 pounds. Within the last four months she has lost approximately 86 pounds. Seven months ago she had a so-called nervous breakdown. She has been rather nervous ever since. For the last two years there has been a slight symmetric enlargement of her thyroid gland, it has enlarged rapidly in the



Fig 417 —Acute ascending exophthalmic goiter two weeks following operation

last four months. She complains of hot flashes, pain, and distress in the region of her heart. Lately her legs tire easily and weakness of the knees has appeared. Her appetite has been very good, but for the past month she has been vomiting in the morning. Within the last week there has been some swelling of the legs and shortness of breath on slight exertion. The skin is flushed and moist. There is a bounding pulse, a loud systolic bruit over the superior thyroid arteries. Heart: There is a loud first sound and systolic murmur, loudest at the base.

The tonsils are chronically infected. The larynx and cords are normal. The basal metabolism rate is plus 62. Eleven days later, with rest and medication, it had fallen to plus 54. The following week it was plus 52. The next day the left superior thyroid artery was ligated under local anesthesia, with very little reaction. Eighteen days later partial thyroidectomy was attempted. When the right lobe had been removed except for the posterior capsule and a small middle lobe attached to the front of the trachea, the patient's condition became so bad that no attempt was made to do any further operative work. The wound was packed with gauze and the patient returned to her room. After five very stormy days, her symptoms had subsided to such an extent that the wound was sutured under gas anesthesia, without removing the patient from her room or bed. Following this her convalescence has been uneventful. The scar is normal notwithstanding the fact that the wound was open for five days. She has been able to return home and feels perfectly well. In about two months she will return to the hospital for a partial removal of the left lobe (Fig. 417).

CASE III. CRISIS IN EXOPHTHALMIC GOITER

This patient, Mrs. J. F., fifty years of age, comes complaining of goiter and dyspnea on exertion. According to her story, she has always had unusually good health and has had no goiter until recently

Five months to a day before admission she received a severe shock in the burning of her home and the financial loss incident thereto. Her nervous excitement of that time has developed since, so that now she is weak and tired, short of breath on slight exertion, has palpitation of the heart, is irritable and has crying spells, sweats much, is always too warm, and has lost 25 pounds in weight. Two months ago a goiter became evident to her. On two occasions she has had diarrhea lasting for a week, and for the past month she has vomited nearly every day. She has not herself noticed her prominent eyes.

Physical examination on entrance shows a very nervous looking woman with prominent staring eyes; with marked tremor

of fingers, lips, and chin, weakness of her legs is so marked she cannot step up onto a chair. Her skin is moist and irregularly flushed. The eye signs of Stellwag, Von Graefe, and Mobius are present. The thyroid is moderately symmetrically enlarged and a systolic bruit can be heard over the lobes and the superior thyroid arteries. There is a very loud slapping first sound over the heart. There is an old deforming arthritis of her finger joints.

Her weight is 150 pounds (normal 175 pounds); blood-pressure, systolic 156, diastolic 80, pulse, 122, temperature 99.4° F. The blood Wassermann is negative, hemoglobin 78 per cent; leukocytes 8800, urine negative.

Lugol's solution, which was administered, was vomited immediately, and the vomiting of everything swallowed continued for many days. Her nights were sleepless, her actions wild. Her pulse ran constantly at a rate of 120 to 140, and once, a week later, reached 170 per minute.

Her bad evident condition at once required the administration of fluids per rectum. Ten per cent glucose solution was given by the drop method and 30 drops of Lugol's solution three times a day. Morphium in fairly large doses was administered regularly, and at first an occasional dose of sodium iodid was given intravenously. At the end of a week, her condition being worse, the continuous administration of normal salt solution by hypodermoclysis was resorted to, with evident improvement as regards heart action and general condition, but with no effect on the vomiting. Ten days after entering the hospital her pulse-rate was fairly even at 90 and 100, and this rate has continued since.

After eighteen days of constant vomiting she suddenly expressed a desire for waffles and sausages, which she ate and retained. Later that day she took and retained a quart of buttermilk. Since then, though vomiting frequently, she has been able to keep enough food to permit the discontinuance of proctoclysis. With the first retention of food a marked improvement in her mental and physical condition was manifest.

No effort at estimating the basal metabolic rate was made.

during her early weeks in the hospital. It is now, at the end of four weeks, reported as plus 57.

This case illustrates dramatically the phase called crisis. Seldom, fortunately, are crises so severe. Medical death occurs often if such a patient is not most carefully handled. With our present knowledge of the condition the surgeon who would attempt operation on such a one would have much to explain.

This patient is too ill for operation at the present time. She might stand a ligation of one of the superior thyroid arteries under local anesthesia. Recently we had occasion to look up



Fig. 418 — Three days after crisis.

our mortality in these severe cases, and, much to our surprise, found that all of the surgical deaths had followed ligation. Since beginning the use of iodine we have ligated only a few. An interesting feature of this case is that we did not feel that the administration of a large amount of iodine gave the benefit that it usually does. We have decided to discontinue the iodine for ten days. If she gets worse we can feel reasonably certain that she would have died a medical death without the iodine. If she continues to improve we will remain in doubt whether iodine ever was a factor in her recovery.

Notable features of this case are: The onset of toxemia after psychic shock; the early date at which crisis was reached—four months; the severity of crisis, and finally, the relative failure of Lugol's solution to influence the severity of the condition. No one can pass finally on the last statement (Fig. 418).

CASE IV. LATE EXOPHTHALMIC OR EDUCATED. GOITER WITH RECURRING CRISIS

This patient, Miss H. S., aged forty. Chief complaint is nervousness and a rapid pulse after slight excitement or exercise. She flushes easily. For the last month all of these symptoms have been exaggerated. Pneumonia fifteen years ago with an uneventful convalescence. Eight years ago she became very nervous, badly rundown, and lost about 40 pounds, at which time a diagnosis of exophthalmic goiter was made. She kept very quiet, but not actually in bed, for about a year. During this time exophthalmos appeared with a complete change in her facial expression. The following year there was some improvement, in which she gained weight and strength. There have, since then, been some ups and downs in her nervous symptoms, always suffering from headaches, some palpitation of the heart, and not quite her normal self. Six months ago she had a very bad cold. Since then there has been a steady loss in weight, with increasing weakness and tremor. The last two months have been the worst since the first year of her illness, and she has lost 20 pounds. A slight swelling of both ankles has appeared recently. Tired and depressed, appetite good; she sleeps well. There has been no vomiting or diarrhea, nor has there been any change in her facial expression in the last six years.

Physical Examination.—Skin irregularly flushed. The thyroid is small and symmetric. There is a loud systolic murmur over the heart. Lungs are negative except for poor expansion. Blood-pressure 160/80. Pulse 90. Basal metabolic rate plus 48.

This case typifies the late exophthalmic with an acute exacerbation of symptoms. After ten days of rest in bed, Lugol's solution, and a diet containing from 4500 to 5000 calories per day,

rich in easily assimilated carbohydrates, a partial thyroidectomy can be done with practically no risk. At this stage the storm is practically over, and most of the damage to the vital organs has been done.

The basal metabolic rate in this case is higher than we usually find it, and from this finding a partial thyroidectomy may



Fig. 419—Educated goiter Operation performed years after her first symptoms

give much relief. But, on the whole, this group of cases is given less relief from surgical treatment than at any other stage (Fig. 419).

OPERATION

The technic which we use for partial thyroidectomy does not differ fundamentally from that which is used in most of the clinics of America.

Before the initial incision is made across its proposed path, two longitudinal cuts are made just through the outer skin on each side of the midline of the neck. This enables an accurate closure of the skin flaps. A transverse "Kocher" incision is made through the skin, fat, and platysma. The flaps above and below are dissected away from the superficial layer of the deep fascia of the neck. The deep fascia is then opened longitudinally

Notable features of this case are: The onset of toxemia after psychic shock; the early date at which crisis was reached—four months; the severity of crisis; and finally, the relative failure of Lugol's solution to influence the severity of the condition. No one can pass finally on the last statement (Fig. 418).

CASE IV. LATE EXOPHTHALMIC OR EDUCATED, GOITER WITH RECURRING CRISIS

This patient, Miss H. S., aged forty. Chief complaint is nervousness and a rapid pulse after slight excitement or exercise. She flushes easily. For the last month all of these symptoms have been exaggerated. Pneumonia fifteen years ago with an uneventful convalescence. Eight years ago she became very nervous, badly rundown, and lost about 40 pounds, at which time a diagnosis of exophthalmic goiter was made. She kept very quiet, but not actually in bed, for about a year. During this time exophthalmos appeared with a complete change in her facial expression. The following year there was some improvement, in which she gained weight and strength. There have, since then, been some ups and downs in her nervous symptoms, always suffering from headaches, some palpitation of the heart, and not quite her normal self. Six months ago she had a very bad cold. Since then there has been a steady loss in weight, with increasing weakness and tremor. The last two months have been the worst since the first year of her illness, and she has lost 20 pounds. A slight swelling of both ankles has appeared recently. Tired and depressed, appetite good; she sleeps well. There has been no vomiting or diarrhea, nor has there been any change in her facial expression in the last six years.

Physical Examination.—Skin irregularly flushed. The thyroid is small and symmetric. There is a loud systolic murmur over the heart. Lungs are negative except for poor expansion. Blood-pressure 160, 80. Pulse 90. Basal metabolic rate plus 48.

This case typifies the late exophthalmic with an acute exacerbation of symptoms. After ten days of rest in bed, Lugol's solution, and a diet containing from 4500 to 5000 calories per day,

Except in unusually long lobes, and those that have a small adenoma high in the pole, it is rarely necessary to cut the ribbon-shaped muscles in front of the gland. The posterior capsule is sutured over and a small rubber drain left on each side. The fascia of the neck is whipped together with catgut. The platysma muscle is repaired with interrupted twenty-day chromic catgut sutures. Skin clips are used, which are removed in forty-eight hours.

Postoperative Treatment.—The dressing, which is held in place with rubber bands (Fig. 421), is very comfortable to the patient and holds the dressings firmly in place. Immediately



Fig 421 —Dressing held with rubber bands.

following the operation these patients receive by hypodermoclysis 2000 c.c. of saline solution, to which has been added a small amount of novocain solution. morphin in $\frac{1}{8}$ -grain doses is given every four hours for forty-eight hours. The administration of Lugol's solution is continued by rectum until all vomiting has stopped. The constant desire to cough is greatly lessened by a vapor which contains a small quantity of menthol, oil of pine needles, paregoric added to milk of magnesia as a base. On the third, fourth, and fifth days we have found that hot boric acid applications give much relief to the extreme soreness most of the people have.

General Remarks.—It is evident from the amount of interest and voluminous literature which has appeared on exophthalmic goiter within the last few years that none of us is quite satisfied with its present status. We usually think of the thyroid gland as the chief offender in these cases, and it probably is, but the other ductless glands must play an important rôle too.

These cases should be studied individually by an internist. A great deal of advance in our knowledge of goiter has come within the last few years from the studies of these men. The subject has so many particular and interesting phases that it is impossible to do more than touch upon a few of them.

We have with us this morning, Dr. Blackford, who has studied all of our cases. I shall ask him to talk to you on some of the interesting phases of exophthalmic goiter.

DR BLACKFORD My interest in exophthalmic goiter goes back to 1910. These years have given opportunity to observe many changes in the treatment of this disease, and to see the relative merits of improvements suggested from time to time. During this period there have been three definite stages of progress. First, the thyroidectomy used before 1912; second, multistage operations (1912-1922) following medical observation to determine the best time for operation, and third, the use of iodine in preoperative treatment, recently suggested by Plummer.

The first of these periods was characterized by improvements in surgical technic. The best thyroidectomies done in 1912 were technically about as well done as those of today. It was not then recognized, however, that removal of the thyroid should never be considered an emergency operation done to save the life of the very ill patient in crisis. The failure to recognize this fact resulted in a gross surgical mortality of approximately 4 per cent in the best hands and a mortality in young people that was as high as 27 per cent. These figures were slightly improved in the several years before 1912, but there was no radical change made until the second period.

Multistage operations were introduced in 1912. At that time it was first recognized that the disease usually approximates the characteristic course as outlined by Dr. Mason. It

was further recognized that no surgical interference should be attempted while the patient was critically ill or was getting worse. This selection of a proper time for operation and the introduction of lesser surgical procedures before attempting thyroidectomy reduced the surgical mortality to approximately 2.6 per cent. for all ages, a remarkable improvement.

We saw during that period a considerable number of patients every year who came to us critically ill and died medical deaths in spite of receiving all the treatment then known. Medical deaths were approximately as frequent as deaths following operation. These medical deaths, added to the surgical deaths, put the actual mortality of the disease before 1922 at nearly 6 per cent.

The average death in the acute fulminating crisis occurred eight months after the onset of the disease. I have seen exophthalmic goiter kill a patient within seven weeks from the first ascertainable symptoms. If we omit the acute deaths, then the average death from the disease occurred seven years after the onset of symptoms, a figure which probably approximates the average clinical duration of the toxemia of exophthalmic goiter. Death following thyroidectomy was unusual. In our clinic we have had no death following thyroidectomy for exophthalmic goiter, but have had several deaths following ligation. In fact, we recognized two years ago that ligation was often a dangerous procedure.

In 1922 Plummer first brought out his work on the use of iodine in treating the crisis of exophthalmic goiter. We have followed his work with great interest because of the marked improvement in statistical figures which have followed its use. The medical mortality has been practically done away with by its use, and the surgical mortality has been reduced to a small fraction of what it was in 1921. We have had no death from exophthalmic goiter thus far where this treatment has been used; this fact, coupled with reports from other sources, convince us that this use of iodine is a great therapeutic advance in the treatment of the disease.

The exophthalmic goiter patient uses up iodine much faster

than the normal person. It has been hypothesized that part of the excess of thyroxin present in exophthalmic goiter is deficient one molecule of iodine, and that the abnormal thyroxin molecule is highly toxic, therefore in exophthalmic goiter we have a dysthyroidism in addition to hyperthyroidism. The feeding of iodine converts the abnormal thyroxin molecule to the normal molecule during the actual administration of considerable quantities of iodine, changing the nature of the intoxication from dysthyroidism with hyperthyroidism to a relatively pure hyperthyroidism. This conversion is, however, very short lived and the disease rapidly changes the normal molecule back to the abnormal after the discontinuance of the drug. This hypothesis, whether or not finally proved correct, gives an excellent working basis for the use of iodine and gives an excellent idea of what to expect from it.

Iodine will cause a very rapid improvement in the symptoms of a patient suffering from acute ascending exophthalmic goiter; and it will cause a very rapid relief from the marked symptoms found in crisis. We must conclude that abnormal thyroxin is present in large amount at this stage of the disease. Within one to three weeks, and often within forty-eight hours, the patient who seems in danger of death will usually become a relatively normal individual with moderate or marked reduction in the metabolic rate. That part of the toxemia typical of exophthalmic goiter, as distinguished from adenomatous intoxication, is manifested by. Extreme nervousness; mental instability and even delirium, by very marked vasomotor phenomena, by marked susceptibility to infection (particularly tonsillitis), and by muscular weakness, particularly quadriceps weakness. The most remarkable improvement is in the mental instability, which usually shows marked improvement within forty-eight hours.

Case III in this report is apparently an exception. There are occasionally cases which receive no apparent benefit from iodine. Weeks of observation and previous experience with many hundreds of other cases make us feel sure that Case III would have died without iodine. It has been given not only in the form of Lugol's solution, but repeatedly by the intravenous administration of sodium iodide.

The clinical effect of iodine medication is then to transform a state of marked dysthyroidism plus hyperthyroidism to a state of moderate or marked hyperthyroidism. Hyperthyroidism is the state produced by feeding overdosage of thyroid extract to a normal individual, and hyperthyroidism exists in the patient suffering from a toxic adenoma.

It must be emphasized that the effect of iodine medication is very short lived and is not curative for the disease. The dose should be doubled or trebled for two days before and two days following operation. It may then be discontinued.

The educated gland type of exophthalmic goiter does not show usually any such dramatic improvement from iodine medication. We have used the treatment, however, because the tendency seems to be toward improvement and because it necessitates hospital treatment and observation for a period before operation.

In closing, I would remark that the diagnosis of exophthalmic goiter is usually easy. The typical case can be diagnosed by anyone who has seen a similar case before. Less marked cases have symptoms which closely imitate neurasthenia and nervous exhaustion. The mild toxemia in certain adenomata also closely imitates the symptoms of exophthalmic goiter. These facts have caused much confusion in reaching a definite conclusion regarding any method of treatment. Iodine will certainly do great harm with a toxic adenoma and may cause the non-toxic adenoma to become toxic. This fact makes it necessary to be keen in the differential diagnosis of these conditions if the treatment is to be safely used. It makes it also necessary to differentiate neurasthenia from mild exophthalmic goiter. The "forme frustre" type of exophthalmic in my experience does not exist. Such a diagnosis has, however, been responsible for many thyroidectomies on nervous exhaustion patients and occasionally has greatly improved mortality statistics in published series of cases.

A method of treatment which reduces mortality and morbidity is worthy of use. We feel that there has been no comparable improvement in the treatment of this disease since thyroidectomy was introduced.



*Reprinted from the Medical Journal and Record
for June 7, 1933*

UTERINE HEMORRHAGE

*With Clinical Observations on the Use of
Ergotamine Tartrate*

J. SANTE DIASIO, M.D.

Adjunct Assistant Visiting Gynecologist, Columbus Hospital
New York

Uterine hemorrhage is one of the most important clinical signs of diseases of women. Not infrequently it is a source of serious worry to the physician, particularly when it is sudden, profuse or recurrent, and when the bleeding point is not accessible.

The clinical aspects of uterine hemorrhage have usually been discussed from a symptomatic classification, namely, menorrhagia, when the menstrual flow lasts too long, is too profuse or occurs too soon, and metrorrhagia, when the hemorrhage occurs independently of the menses. Modern gynecology should discard this antiquated classification and study the condition from the standpoint of functional disturbance and anatomical changes.

CLASSIFICATION AND CAUSES

Uterine hemorrhage signifies either a disturbance of the menstrual flow or bleeding independent of menstruation. A simple classification is one suggested by Cullen (1) who divided the conditions causing uterine hemorrhage into two groups: 1, those dependent on recent pregnancy, and 2, those independent of recent pregnancy. Uterine hemorrhage dependent on recent pregnancy occurs with 1, premature separation of the placenta; 2, retained membranes; 3, hydatidiform mole; 4, chorioepithelioma; 5, tubal pregnancy, and 6, pregnancy in one horn of a bicornate uterus. Uterine hemorrhage oc-

curing independently of recent pregnancy is classed under one of the following groups: 1, hemorrhage due to constitutional conditions, 2, hemorrhage due to benign changes in the mucosa of the cervix and body of the uterus; 3, hemorrhage due to malignant changes in the mucosa of the cervix and body of the uterus, 4, hemorrhage due to the presence of uterine tumors, 5, hemorrhage due to functional disturbances of the uterus and ovaries, and 6, hemorrhage due to disease of the adnexa.

DIAGNOSIS

As Lawson Tait put it many years ago, any practitioner seriously neglects his duty who undertakes the treatment of uterine bleeding without first carefully informing his patient of the utter futility of any therapy until there is a clear conception of the conditions present. Miller (2) says, "It is impossible to institute rational treatment without an accurate diagnosis; since uterine hemorrhage is only a symptom, not a disease in itself, it is plainly impossible to relieve it without knowing whence and why it arises." The most important point in the management of uterine hemorrhage is to establish the cause of the bleeding by a careful anamnesis, a general physical examination and a meticulous pelvic study. In some instances, blood examinations are necessary to determine the degree of anemia, and if a blood dyscrasia is suspected as the cause of the hemorrhage, the blood should be tested for its coagulability and calcium content. Diagnostic curettage and microscopic examination of the scrapings are frequently indicated, especially to eliminate polypi, malignancy and other intrauterine conditions.

PROGNOSIS

The prognosis in uterine hemorrhage depends upon two factors, namely, the cause, which may of itself tend toward a fatal issue as in malignant disease, and the amount and persistence of the bleeding,

for the constant loss of blood always results in a secondary anemia that may be so pronounced as to impair the patient's resistance to intercurrent disease or to any operative procedure that may become necessary.

TREATMENT

Since the advent of radiation therapy, the impression has been created that radium and x-rays have displaced other forms of treatment in gynecological diseases accompanied by bleeding. It is obvious that each method of treatment has definite indications and limitations, and that the indications for each should not overlap.

The treatment of uterine hemorrhage is considered by Polak (3) under two headings, i.e., the immediate control of the uterine hemorrhage and the correction of its cause or causes.

Direct hemostatic measures should be employed for the immediate control. These include rest in bed; topical applications; electricity, galvanism, the roentgen rays and radium; the administration of drugs and sera; and hygienic measures. Direct blood transfusion is sometimes necessary when the anemia is profound. The management and correction of the cause which produces the bleeding include such surgical measures as curettement, salpingectomy, oophorectomy, myomectomy and hysterectomy.

The foregoing outlined methods of treatment with the exception of drug therapy have been satisfactorily standardized and generally accepted; consequently they have not been included in this discussion. Hence the presentation of the subject comprises the employment of a hemostatic expedient that is most effective for the control of uterine hemorrhage, when it is important to check the flow promptly even before an accurate diagnosis as to its cause can be made.

DRUG THERAPY

The number of hemostatic agents that have been advocated for the control of uterine hemorrhage is legion. Perhaps the two best known and most important medicaments are pituitary extracts and ergot preparations.

Apropos of pituitary extracts it may briefly be said that they are powerful but their action wanes too rapidly and subsequent injections are less effective than the first one. They also act on the arterioles as well as on the uterus, raising the blood pressure to a considerable degree. Rusby, Bliss and Ballard (4) state emphatically that the use of pituitary extracts in parturition is still to be regarded as in the experimental stage. On the other hand, ergot appears to be the best therapeutic agent for uterine hemostasis because its action is more lasting than any other medicament and the dose may be repeated with no diminution in its effect.

ERGOT THERAPY

It may candidly be admitted at the outset that up to a few years ago there existed much dissatisfaction among physicians with the results obtained from ergot. It was as recent as 1928 that Nelson and Pattee (5) pointed out for the first time that many of these poor results were due to the use of preparations containing but little or none of the specific alkaloids to which the characteristic action of ergot is due. Before proceeding further with this fascinating subject it may not be amiss to consider briefly the history of ergot.

It was an American physician, John Stearns (6) who, in 1807, published the first paper on the use of ergot in medicine. In 1822, however, he firmly established its advantages in obstetrics in a masterly essay (7).

The search for the active principles of ergot began

in 1875, when Tanret (8) succeeded in extracting from ergot two well defined alkaloids which he called, respectively, crystalline and amorphous ergotinine. In 1906, Kraft (9) isolated an alkaloid which he named hydroergotinine. Almost simultaneously, but independently, Barger and Carr (10) in England discovered ergotoxine. Both hydroergotinine and ergotoxine were soon found to be identical with the amorphous ergotinine of Tanret, which by loss of water is readily converted into its less active anhydride, the latter being crystalline ergotinine.

Despite these distinct advances in the chemical study of ergot, the problem was not solved from the viewpoint of practical therapeutics and pharmacy. Confusion and uncertainty still prevailed to the extent that it was stated openly that the powerful effect of fresh ergot on the uterus could not possibly be attributed exclusively to the comparatively small quantity of alkaloids found in it. Inspired perhaps by the then recent studies on epinephrine and similar amines, further investigations showed the presence of a number of other active substances, especially histamine, tyramine and acetylcholine. Here the matter rested until the isolation of a second active alkaloid, ergotamine, by Stoll (11) in 1918. Subsequently many studies have been conducted to determine the principles upon which the characteristic action of ergot depends. While histamine, tyramine, ergotoxine and ergotamine are admittedly the active substances in ergot, yet Nelson and Pattee (12) state that, "there is no satisfactory clinical evidence for the value of tyramine or ergotoxine in obstetrics and gynecology; the evidence for histamine is somewhat questionable; adequate clinical as well as experimental evidence exists to justify the conclusion that the alkaloid ergotamine is the most important constituent of ergot; and the one whose presence in ergot preparations should be insured."

CHEMICOPHARMACOLOGICAL PROPERTIES OF
ERGOTAMINE

Ergotamine is a newly discovered crystalline alkaloid of ergot. It is readily decomposed by oxidation and it is for this reason that galenic preparations of ergot deteriorate rapidly. Commercially, ergotamine is obtainable in stable form as the tartaric acid salt, ergotamine tartrate, or gynergen-Sandoz (13). As borne out by the conclusive reports of Rothlin (14, 15, 16 and 17) and others, ergotamine produces a notable increase in tonus and rhythmic contractions of the uterus when administered intravenously to rabbits.

ERGOTAMINE TARTRATE THERAPY

The successful treatment of active uterine hemorrhage with ergotamine tartrate has been engaging the attention of gynecologists and obstetricians abroad as well as in this country as testified to by the reports of Bourne and Burn (18), Doederlein (19), Fohr (20), Gremmee (21), Greenhill (22), Guggisberg (23), Hamm (24, 25). Many of the latest pharmacopœias now specify that ergot preparations must be standardized by their alkaloidal content. Furthermore, the Committee on Bio-assays of the League of Nations has recently recommended that ergotamine be used as the standard of comparison in the evaluation of the activity of all ergot products. The encyclopedic study on the pharmacology of ergot by Thompson (26) proves conclusively that the most trustworthy method of standardization is bio-assay against the alkaloids, of which ergotamine is the most convenient to use. This latter conclusion is concurred in by Smith and Stohlman (27): "We believe that the standard of reference we used in this work, viz, the crystalline ergotamine tartrate, which we are assured has a definite and constant alkaloidal content with well defined physical constants, should meet all the requirements of a standard."

The foregoing should suffice to support my view that in ergotamine tartrate or the Council accepted gynergen we have a dependable, uterine hemostatic. I have used it in a series of one hundred cases of uterine hemorrhage and my experience has enabled me to arrive at the following conclusions:

SUMMARY AND CONCLUSIONS

This study, based on a series of one hundred hospital and private cases of uterine hemorrhage observed over a period of three years, demonstrates quite satisfactorily the efficacy of ergotamine tartrate as a hemostatic in active uterine hemorrhage where it is imperative for the physician to first control the bleeding and later establish its cause.

1. This series of one hundred cases is divided into thirty-nine private and sixty-one hospital or clinic cases. It comprises fifteen cases of postpartum hemorrhage, twenty-five cases of incomplete abortion, five cases of subinvolution, ten cases of protracted and profuse lochial discharge, five cases of climacteric bleeding, ten cases of uterine bleeding due to fibroids, and thirty-five cases of adnexitis accompanied by bleeding.

2. The ergotamine tartrate was administered intramuscularly and orally. One ampule of one c. c. was injected into the buttock and repeated in one half hour in the majority of the cases. This was followed by the administration of one tablet orally every three hours. Three to four days were required to entirely and effectively control the active uterine hemorrhage. In addition, rest in bed and Fowler's posture were instituted. In only three cases of the entire series was it necessary to resort to vaginal packing.

3. The oral administration of the tablets was found to be quite acceptable to the patients since they are free from the unpleasant odor and taste of the fluid extract of ergot. None of the patients complained of pain or soreness at the site of the

injections nor were there any signs of abscess formation.

4. In all of the cases of this series it was noted that the injection of ergotamine tartrate promptly induced a firm, tonic contraction of the uterus, more prolonged than that of pituitary preparations. This is in accord with the findings of Brumby (28), Levy (29), Bourne and Burn (30), Greenhill (31), and Hellman (32).

5. In the cases of postpartum hemorrhage, the administration of ergotamine tartrate by intramuscular injection was attended by an almost immediate control of the hemorrhage. It was only necessary to give a second injection after one half-hour interval, followed by the administration of tablets per os, one every three hours for four days to maintain the ergot effects initiated by the first injection.

6. Since the completion of this study, I have routinely employed ergotamine tartrate as a prophylactic for postpartum hemorrhage in my obstetrical work by the following method. Immediately upon the termination of the third stage of labor one c c is injected intramuscularly and after ten hours one tablet is administered every three hours for three doses. This plan of treatment proves efficacious and prevents the occurrence of postpartum hemorrhage due to atony by keeping the uterus in a state of tonic contraction for twenty-four hours after delivery.

7. Ergotamine tartrate proved quite efficient in incomplete abortion. Only three of the twenty-five cases required a curettage which incidentally was performed with greater facility because the uterus was already rendered hard and firm by the action of the drug.

8. It is gratifying to note that the cases of subinvolution as well as those of lochial retention responded quite admirably to ergotamine tartrate therapy. In the five cases of subinvolution, the process of involution was arrested on the third day.

in two cases and on the fifth day in the other three. Under the influence of ergotamine tartrate, the processes of involution again rapidly progressed so that in the former two cases the uterus disappeared behind the symphysis on the tenth day, while in the latter three cases the process was completed on the eleventh day. The varied therapeutic results encountered in the past with the galemeal preparations are readily explained by the extensive study of Schubel and Straub (33) and Oettel (34).

9. In the cases of hemorrhage due to uterine fibroids where the pathological changes, present in the uterine walls, weaken their contractility, ergotamine tartrate brought about a cessation of the profuse bleeding in all ten cases by increasing the uterine tonus. The same result was obtained in the five cases of climacteric bleeding in which, though the ovarian dysfunction was the starting point, the functional insufficiency and senility of the uterus was directly responsible.

10. In adnexitis of gonorrheal origin uterine bleeding is a frequent concomitant symptom (35) as it was present in all the thirty-five cases reported in this study. Ergotamine tartrate was found to be effective in controlling the active bleeding without the necessity of resorting to other measures, and it was noted, at the same time, that it also prevented a menorrhagia at the next catamenia.

11. Because of the reliability of the powerful and lasting action promptly induced by ergotamine tartrate, we do not hesitate to unreservedly recommend it to physicians as an adequate and satisfactory therapeutic agent for the complete and immediate hemostasis in those cases of active and profuse uterine hemorrhage where it is not judicious to temporize in determining the etiological factor of the hemorrhage.

BIBLIOGRAPHY

1. CULLEN, T S : *J. A. M. A.*, 78:1592, May 27, 1922.
2. MILIFR, C. J.: *Clinical Gynecology*, St. Louis: C. V. Mosby Co, 1932.



CARCINOMA OF THE THYROID

THIS man is fifty-nine years of age. Has been employed for many years as a railroad clerk. His family history is negative except one sister died of carcinoma of the breast at the age of forty. Married thirty years. No children. Except for a very severe attack of typhoid fever at the age of twenty-five, has always been healthy. He came to the clinic complaining of an enlargement of the right side of the neck, which has increased the past year.

At the age of sixteen he was strangled badly in a fight. Shortly afterward a small lump appeared on the right side of the neck. Twenty years later this began to enlarge, and continued to increase for about two years, until it reached the size of a lemon. One year ago it began to grow again, reaching the size it is today. There is considerable shortness of breath on exertion and a sensation of choking. At these times his breathing sounds as if he were blowing through a tube.

Physical examination is negative. *x*-Ray shows a marked displacement of the trachea to the left. The basal metabolic rate determined was somewhat difficult because the patient was unable to lie down without coughing. However, the report is fairly satisfactory, although the reading was taken in a sitting position. It is plus 9. The growth is practically all in the right lobe of the thyroid. It is nodular, firmly fixed, and several of the nodules in front are soft. This is a cystic degeneration covering, we believe, a malignant growth.

The tumor which he felt in his neck at the age of sixteen may have been a hemorrhage in the gland, but was probably an adenoma, which again was noticed and which became somewhat larger at the age of thirty-six. The pointed thing about the story is that the rapid growth within a year following a long period of inactivity alone is very suggestive of malignancy.

In no other organ of the body is malignancy so concealed as in the thyroid. In all cases that we have seen that could be diagnosed clinically rupture of the true capsule of the gland had taken place. These patients came for the relief of tension and pressure, or pressure upon the trachea, as is present in this case. Various observers state that malignancy occurs in from 1 to 2 per cent of definitely enlarged thyroids. It is more frequently found in women. Ninety-five per cent of these develop from fetal adenoma. These circumscribed masses of thyroid tissue are non-lobulated, and in the early stages are not capsulated nor do they contain iodine or colloid material. They usually remain stationary throughout life, but when, for some unknown reason, the cells begin to proliferate we have the beginning of carcinoma. These masses can be detected macroscopically by their yellowish color. The nearer they are to normal thyroid tissue, the less likely are they to become malignant.

When the carcinoma reaches the capsule of the thyroid gland, we find hard nodular tumors, and finally, when they break through the lobe, this becomes firmly fixed and widely adherent to the surrounding tissue, as is found in this case.

The lymphatics of the gland are numerous, but the blood-supply is so overwhelmingly predominant that metastases usually come through the blood-stream. This explains why metastases in bones occur more often from cancer of the thyroid than from any other organ. A peculiar trait of these malignant metastases is that they have a tendency to revert back to the structure of normal glandular tissue. A case has been reported in which a complete thyroidectomy had been performed for malignancy, with no unusual developments until a metastatic growth was removed, when marked myxedema soon developed. Before metastases develop these tumors are slow growing, and with the relief of pressure symptoms by operation, followed by a course of deep x-ray therapy, the patients usually go back to work and are fairly comfortable for a year or two.

The growth in this patient is beginning to press on the trachea to such an extent that we have advised surgery for immediate relief (Fig 422).

Operation.—When the cancerous growth is limited to the thyroid gland the operation is no different from that required for large adenoma. In this case the disease has extended into the tissues of the neck. The muscles and great vessels are attached firmly to the gland.

A large angular incision is made and flaps turned back. No effort is made to save the muscles and small blood-vessels in front of the gland. No effort is made to separate the outer capsule. The line of the incision is entirely in healthy tissue until the neighborhood of the large vessels is reached. When the mass has been well exposed, hemostats are applied around the base

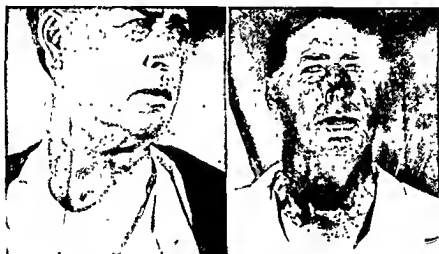

Fig 422—Carcinoma of the thyroid before and six weeks after operation.

and the growth is removed with a scalpel. Bleeding around the edges is controlled by ligation. The middle of the cut surface is cauterized, which cauterization stops the profuse oozing and causes a further destruction of gland tissue. The cavity is packed with gauze and the flaps are pulled back and tacked into place. This operation is a decompression only. The case is too late for a cure

Remarks.—It has been stated that iodine given the mother during pregnancy prevents fetal adenoma in the children. If this statement is true, this would be the one and only way of preventing cancer of the thyroid in the next generation. It

would be impossible to remove all fetal adenomata surgically as a prophylactic for cancer. Many of them are small. Even if large enough to be detected, no power of persuasion could induce our people to have them removed on the chance of cancers developing later in life.

CLINIC OF DR. ALEXANDER H. PEACOCK

MINOR PRIVATE, VIRGINIA MASON, AND PROVIDENCE HOSPITALS,
SEATTLE, WASHINGTON

PROSTATECTOMY IN THE ADVANCED YEARS. FACTORS IN DETERMINING UPON OPERATION. GETTING THE PATIENT IN CONDITION TO SURVIVE THE OPERA- TION. SOME POINTS OF TECHNIC

THE first patient we have to operate upon this morning is a man of rather advanced age—eighty-five years. He has lived a careful life and should be a better risk than the average. He states that for the past seven years he has been catheterizing himself on account of retention of urine from a large prostate. This he has been doing every three to six hours. When the bladder fills up he gets excruciating pains.

Twenty years ago he developed a right inguinal hernia and has been wearing a truss to keep it in place, but this hernia has been constantly getting larger. Five years ago he had a severe attack of angina pectoris, which confined him to bed for several weeks. Since that time he has had a number of light attacks which have deterred several surgeons from operating on his prostate.

He was admitted to the hospital with a right epididymitis. He was very feeble and in great pain. He called constantly for the catheter to empty his bladder and he was confined to his bed. He had some nausea, was unable to eat, taking only liquids.

Examination.—The patient is of slender build. His blood-pressure is systolic, 230 millimeters, diastolic 110 millimeters. There is a slight anemia, as indicated by the blood-count—erythrocytes 3,700,000, hemoglobin 72 per cent. The heart shows some arhythmia and duplication of the second sounds;

no murmurs and no enlargement. The arteries are markedly sclerosed. The right epididymis shows considerable enlargement throughout and it is very tender. There is a large bilateral, indirect, inguinal hernia. Rectal examination reveals a rigid stricture of the anus, admitting only the tip of the finger. The bladder was catheterized with a No. 15 rubber catheter and 3 ounces of urine were withdrawn. This amount gave him a great deal of pain.

After a week in bed the phthalein test gave us 18 and 40 per cent. For the preliminary treatment an inlying catheter was employed. He objected to this at first, but we insisted on making him wear it. We also forced him out of bed, and from a feeble, bedridden patient, we got him walking around the hospital halls in a week or two. This improved his strength and a marked change was noticed in him.

This brings up two important points. (1) Keep your elderly patients out of bed as much as possible and oblige them to wait upon themselves. Elderly people soon become childlike and will request as much waiting on as a very small child. This keeping your patient out of bed also applies to the postoperative management of prostatectomy. They soon learn that they feel better, sleep better, and eat better when they are up, at least in a chair. They become more encouraged and the mental effect is very stimulating. Have the nurse read to the patient the current events of the day from the newspapers, which keeps up his interest in life and takes his mind from the immediate illness.

(2) The point that comes to my mind right now is the choice of the two-stage prostatectomy, or a preliminary period, wearing an inlying catheter, and performing the prostatectomy at one sitting. I believe this latter is the better for this reason, with a catheter in the bladder gradual decompression can be accomplished, and the renal balance is not upset by the sudden release of a greatly distended bladder.

It has been my constant experience, as it has probably been yours, that the minute the distended bladder is opened there is an immediate fall of blood-pressure of 40 to 50 millimeters. In some of these falls there is a severe disturbance in the circula-

tion of the kidney due to this lowered pressure. The filtering kidney will not work and urinary suppression has resulted in coma and death in forty-eight to seventy-two hours. The patient's death is charged to *cystotomy*. On the other hand, the catheter can very nicely control this situation and can be withdrawn if danger signs arise, which will be indicated by rapidly falling blood-pressure and diminution of the output of urine, the appearance of albumin in the urine, and a rise in the specific gravity. This inlying catheter gives the kidneys an opportunity to readjust themselves. Many an old prostate has been tided over uremia by giving diuretics and fluids intravenously and subcutaneously and supporting the heart.

This patient's condition in the month's time that he has been wearing this catheter has been greatly improved with the use of digitol. In handling these elderly subjects we must keep in mind that the heart must be watched very closely. Myocardial changes are almost certain to be present and they form an integral part of the kidney function.

I have kept the catheter in this patient now for a month. I have seen his blood-pressure come down from 230 millimeters to 150 millimeters. I have noted a change in strength. From nausea and vomiting he is now able to eat a very good meal three times a day. His heart is regular, not intermittent, his pulse is full and strong, and he is able to walk around the hospital grounds. A check up on the phthalein shows a 30 to 45 per cent. for the first and second hours, and I feel reasonably sure that he should survive the prostatectomy.

To sum up, he has (1) adenofibroma of the prostate, (2) stricture of the anus, (3) double inguinal and femoral hernia, and (4) angina pectoris. I am taking this chance with him because his heart is good, the kidney function is normal, and life to him, with the pain and danger of the catheter, is a great burden. As we have heard patients remark before, so I have heard him declare, "Doctor, I would rather be dead than live this way."

Operation.—I am choosing nitrous oxid gas for my anesthetic, the patient having had a preliminary injection of mor-

phin I find they take very little anesthetic, and where the operation is rapid, seldom require ether. The secret of a successful anesthetic in these patients is, of course, the amount. You see he has gone to sleep very quietly. I now withdraw the rubber catheter, and in its place substitute a metal catheter with a Guyon curve. I do this for two reasons. First I wish to fill the bladder with a boric solution so as to lift the dome of the bladder well up toward the median line. In some types of contracted bladders this is important and only a few ounces of fluid can be forced into the bladder. This is a type of case where the metal catheter in the bladder makes a very good suprapubic guide in locating a small contracted bladder. The second advantage of this metal catheter I will demonstrate in a few minutes when I put in my packing.

I have now incised the skin and superficial fascia. My assistant places the self-holding retractors and you see this dome at the bottom of the incision. Gently pushing back the peritoneum with a piece of dry gauze I identify the bladder wall by its large veins, which are often tortuous. I carefully search a spot in the bladder wall which is free of veins, being careful never to grasp the bladder with forceps, as I am liable to tear one of these veins. These vessels are frequently cut or torn and form one of the sources of secondary hemorrhage. I now puncture the bladder with a sharp scalpel and insert into its cavity an aspiration tube, which draws off the bladder contents without their running all over the wound and towels. I now put on an extra glove and sleeve on the left hand, and the nurse raises the towel, and insert my index-finger in the rectum. The assistant partly withdraws the metal catheter. With my right index-finger I penetrate the vesicle and the urethra, force it in until I have split the membrane and found my line of cleavage for enucleation. The left lobe is the larger, therefore I shell that out first. These lobes are similar to fibroids. Next I feel a small tongue of tissue in the middle lobe which is blocking the urethra. This is shelled out with the right lobe. My assistant now will insert the bladder retractor so that I can easily see the capsule of the prostate (Fig. 423). This feels to me like

a small cup. It is contracting nicely and I now push the catheter on into the bladder again. I now withdraw my finger from the rectum. The wall of the capsule is searched for any spurting vessels, and I find none. The nurse is giving me a strip of 2 inch dry gauze which I pack in around the catheter, using a pair of curved sponge forceps (Fig. 424). This is packed very

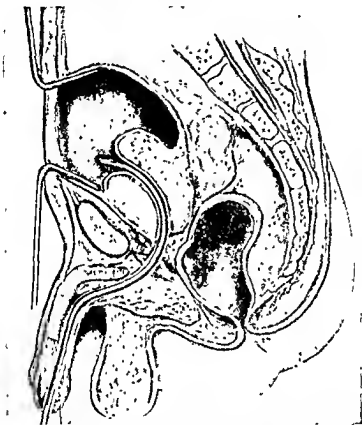


Fig. 423.—This shows the bladder opened, the Guyon catheter in the urethra, the prostatic enlargement; also why a large double curved catheter is necessary. The prostatic capsule has been outlined.

tightly around the catheter, so that I know that bleeding cannot occur. It takes the place of the prostate removed.

There are some surgeons who claim they never pack the capsule and never have any bleeding; that clots will form and check the bleeding that way. On questioning the colleagues of the surgeons making these claims, I find they do not tally, that bleeding does occur, and secondary packing is necessary. It is

true that packing gives the patient a certain amount of pain, but the safety offered against hemorrhage, in my opinion, is very good insurance. It can be left in three or four days until the urine loosens it up.

We now examine the rest of the bladder, dry it out well with hot, wet sponges, pick up the edges of the bladder incision, and insert this rubber tube which is $\frac{5}{8}$ inch in diameter.

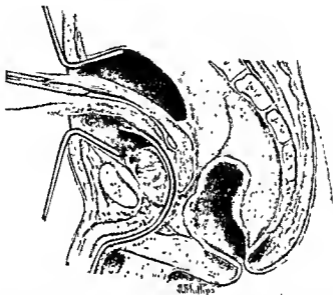


Fig. 424—Where oozing occurs from the prostatic capsule and it is necessary to control it with pressure the metal catheter is reinserted in the urethra and 2-inch gauze packing is placed around the catheter. Curved sponge forceps are very good for this. With the catheter in the urethra it is very easy to get the gauze inside the capsule and not in the bladder itself.

This tubing is rather important, the walls must be stiff enough not to collapse, it should not be too large to irritate, and the holes in it should be opposite one another. Chromic gut is used to close the bladder and I usually use two lines of sutures. The more perfect it is closed and the drier it is kept, the quicker healing will take place.

I now place a cigarette drain in the prevesicle space (Fig. 425). This is quite important, as urine will leak around the

drainage-tube into this space and form a pool which soon becomes infected. I place two or three interrupted sutures in the subcutaneous fascia, two through-and-through silkworm sutures, and close my skin incision with three or four wound clips. You notice that I have small rubber tubing guards on the silkworm gut. This prevents cutting through the skin.

My anesthetizer tells me the patient's pulse is 80 and good quality, blood-pressure 130 millimeters, and the time of the operation has been twenty minutes

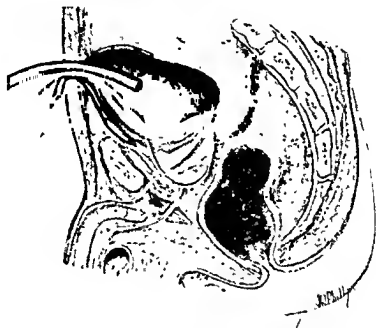

Fig 425.—This shows the gauze packing within the capsule, as it should be. It also shows the proper length of the drainage-tube and the important cigarette drain in the prevesicle space.

The nurse will now put a pneumonia jacket on the patient, a Murphy drip has been ordered, and $\frac{1}{8}$ grain of morphin, as the patient comes out of the anesthetic very rapidly. It is quite important to keep these elderly patients warm, as their circulation is poor.

To sum up: On operating upon these elderly prostates it is necessary to handle them carefully, dexterously, and watch them closely all the time.

HYDROPYELONEPHROSIS. DIFFERENTIAL DIAGNOSIS. LUMBAR EXTRAPERITONEAL NEPHRECTOMY

THIS patient now on the table is largely interesting on account of the differential diagnosis, which I shall go into after giving you a summary of her medical history.

History.—This patient was first examined in March, 1918, at which time a diagnosis was made of tuberculosis of the left kidney, being based upon a renal study and the finding of acid-fast bacilli in the urine. She shortly afterward left the Northwest and located in southern California to build up her health, hoping to throw off this infection. Her chief symptoms were: (1) pain in the bladder, (2) frequency of urination, and (3) backache high in the left lumbar region. She is a trained nurse and is assisting a doctor who watched her symptoms closely.

She is thirty-five years old. In her family history one brother died of tuberculosis of the larynx, and her maternal grandfather died of tuberculosis of the lungs. These are the only known cases in the family. Her own medical history is measles at ten years, mumps at fourteen years, and tonsillitis until she had her tonsils removed ten years ago. She had two molar teeth removed on account of abscesses in 1922. Her appetite has been good, she has steadily gained in weight, and now weighs 162 pounds; height, 5 feet, 5 inches.

She had a slight arthritis a few years ago in her hands, ankles, knees, and shoulders; this was very mild. Ten years ago she began to have pains in the back, a short distance above the iliac crest, which radiated down the left leg. Her back seemed stiff all the time. In 1914 she was given an injection of tuberculin, from which she had a terrific reaction lasting three days. From the reaction and the location of the pain she was given a diagnosis of tuberculosis of the spine. The back pain has continued up to the present time, but steadily lessening in severity. The gynecologic history is entirely normal.

Seven years ago the patient first complained of a slight increase in frequency of urination, then there appeared a series of mild urinary hemorrhages. The appearance of the urine was bright red, blood appeared several hours at a time, always in the morning, and between hemorrhages the urine remained smoky. At this time she was cystoscoped by Dr Ray Jones and informed that she had a golf-hole ureter opening on the right side. It was not possible to enter the left ureter. He said there were tuberculous ulcers present in the bladder wall. Organisms were found in the bladder urine. No pyelograms or x-ray studies were made and the symptoms grew steadily worse. The bladder would empty itself every fifteen to twenty minutes and there was intense pain. She was cystoscoped a month later by Dr C C Tiffin, who also diagnosed tuberculous ulcers of the bladder, and a catheterized specimen of urine again was pronounced positive for tubercle bacilli. Irrigations were made twice a day with phenol, permanganate, and silver nitrate solutions. The hemorrhages disappeared and gradually the acute symptoms subsided. The patient voided every hour and a half to two hours during the day. At present she can go without voiding as long as three hours. Apparently her bladder capacity is 4 ounces. Nocturia occurs three to four times. There is no pain on voiding, but the pain is excessive when the bladder is full. No blood is ever noticed and the urine is practically clear.

I am indebted to Dr. A Elmer Belt, of Los Angeles, for a very careful and complete examination made in August. Her examination is as follows:

Examination.—Short, stocky build, well nourished, and skin tanned with the sun. She has every appearance of excellent health. Breath sounds clear and easily audible throughout, no râles present. Expansion good and equal on both sides. Blood-pressure, systolic 120 millimeters, diastolic 90 millimeters. Pulse-rate 100, good volume, no misbeats. Abdomen moderately fat, no spasticity, slight tenderness over the left kidney, none over the right. There are no scars and no tumors palpated.

In the x-ray plates I am showing you, you will notice the spine reveals an almost complete absorption of the intraver-

tebral disk, and between the second and third lumbar vertebræ, with areas of bony absorption and the approximate absorption of these vertebræ. The joints of these vertebræ are jammed tightly into one another and apparently firmly fixed in this position. There is no evidence of a tuberculous abscess. This is apparently an old tuberculous process with fusion and fixation.

Dr. Charles S. Young, of Los Angeles, states, "My diagnosis of the case is that it is a healed tuberculous disease of the second and third lumbar vertebræ and requires no treatment except a corset support to maintain a good posture."

In Dr. Belt's renal study he makes the following notes: (1) The bladder capacity is found to be 75 c.c. (2) The bladder mucosa appears slightly injected throughout (3) The fundus is nearly normal in appearance and the trigone is definitely injected. (4) There are no areas of ulceration present. (5) The mucosa over the trigone and in the region of the bladder neck are thickened and relatively inelastic. (6) The right ureteral orifice appears normal and function is observed. (7) The left ureteral orifice is hardly visible, surrounded by a scarred, contracted region. It is small and rigidly patent

The right ureter was catheterized with a No. 6 opaque catheter and into the left ureteral orifice a No. 6 olive tip catheter is passed for 5 cm., when an impassible obstruction is met. A smaller catheter did not pass this obstruction. A good flow of urine was obtained from the right kidney, but only a few cubic centimeters from the left

Pyelograms were then made, and you see this film pasted against the window. The right pyelographic shadow reveals a normal pelvis and calices (Fig. 426). A very good shadow of the left kidney is obtained which reveals a large sacculated upper pole and a relatively dense lower pole. This kidney shadow extends from the vault of the diaphragm on the left to a few centimeters above the iliac crest. None of the sodium iodid has entered the left kidney pelvis.

No function was obtained for the phthalein test from the left side in a fifteen-minute period. Stains from the bladder,

right and left kidneys for bacteria, were negative, except for a few staphylococci in the bladder specimen, probably from contamination; no tubercle bacilli and very few leukocytes

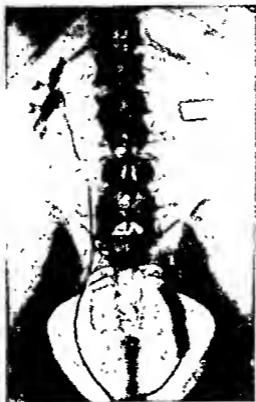

Fig 426—Shows a normal pyelogram of the right kidney, and on the left side where the tip of the catheter is just engaged in the left orifice the ureter is quite large and only partly filled. The left kidney can be faintly seen in outline with an irregular density suggesting lobulation.

Differential Diagnosis.—With this history and with these findings the question is, Is this tuberculosis or is it hydro-nephrosis?

In favor of tuberculosis we have a doubtful family history of this disease, the reports of two laboratories which claim to have found acid-fast bacilli in catheterized urine, and the pres-

ence of ulcers in the bladder, which looked tuberculous by two observers. We know that a cystitis of an acute type was present seven years ago by the patient's own story. Another suspicious symptom of tuberculosis was the hemorrhages, as these are very common with this infection. They are somewhat similar to the hemorrhages from ulcerated lesions in the lungs.

Against tuberculosis we have the following array of facts: To begin with, tuberculosis of the urinary tract, like that of the lungs, is a progressive, steadily advancing disease, only less responsive to rest and treatment than are the lungs. The early symptoms of tuberculosis of the urinary tract are painless frequency of urination; later on, as the tubercle begins to ulcerate, you have symptoms of acute cystitis, the terminal pain, and tenesmus. The fact that this patient cleared up so well after treatment, and all of the lesions healed in the bladder, as revealed by Dr. Belt's examination in August, would largely be against tuberculosis. Many times acute cystitis is cystoscoped and, due to the contracted bladder folds, the highly inflamed mucous membrane with ulcers and bleeding areas, an incorrect diagnosis is apt to be made. Such confused bladder pictures as these have been called tuberculosis, cancer, tumors, and hemorrhagic cystitis. It usually pays to quiet down the acute symptoms, clear up the urine with sedatives, as we all know that pictures change remarkably in a comparatively short time.

This patient could have come in this group of mistaken diagnosis. Another factor against tuberculosis is the patient's general improvement, the absence of all fever, and the inability to again demonstrate the tubercle bacilli. Just before her operation the urine showed numerous pus cells, no blood, and many colon bacilli. As a rule tuberculous urine is cloudy, shows many pus cells, and no bacteria unless the tubercle itself is found. This is very characteristic of tuberculosis of the kidneys or the bladder, to find many pus cells and no organisms. Continued search, however, is usually rewarded by finding the tubercle itself. A guinea-pig inoculation is slow and inaccurate. Persistent staining for organisms is very much better.

If you will look at the pyelogram again you will notice the

large diameter of the ureter. This is unusual in tuberculosis. While we may have a large ureter in this disease, the lumen itself is small and has a moth-eaten outline. The pelves of a tuberculous kidney are quite irregular and may show a cavity, but are not sacculated and ballooned, as this case shows. Another point that is in favor of hydronephrosis over tuberculosis is the mobility of the kidney, which can be easily moved around, showing the absence of perinephritic inflammation which we get so commonly with tuberculous kidneys.

To Sum Up.—Our patient in the past seven years has gained in health and strength, she has no fever, and tuberculosis always carries a low-grade fever. Her hematuria has disappeared, her bladder is not painful, and no tubercle bacilli have been found.

We will now proceed to the nephrectomy. The patient is placed on her right hip. I prefer this to the patient lying on her abdomen, as it gives a much easier access to the ureter in dissecting it down. The table is bent in the middle, and a small pillow is placed under the left shoulder and the left knee, which is drawn up. You see we have plenty of room between the iliac crest and the eleventh rib. I start my incision just below the eleventh rib, following downward over Petit's triangle, bringing the incision slightly forward. In this way we miss the great lumbar muscles and drop immediately into the renal niche. You see the lower pole of the kidney coming into view, and as the retractors are put in place, it almost delivers itself.

The kidney has a lobular surface, is freely movable, and I find but few adhesions. I am now passing my hand over the upper pole. In making these dissections it is quite important to obtain a good line of cleavage. Much time is lost and much difficulty encountered by trying to dissect through layers of fatty capsules instead of getting down next to the capsule at the start. Where the capsule is very adherent to inflammatory perirenal fat, it is much easier to make a subcapsular dissection. I now have the upper pole entirely free and I slip around to the lower pole where I encounter these bands, which you see. I have at times cut these, but once remember an anomalous renal artery entering the very tip of the lower pole. It took a few

minutes to find this bleeding vessel and it was rather embarrassing, so now I always clamp bands before I cut them. The lower pole is free to the pelvis and my next step is to pick up the ureter. This is easily found by running the fingers over the psoas muscle, the floor of which you notice. This ureter, with its thin walls, is rarely found in a tuberculous kidney, but is common, however, in hydronephrosis. I am now clamping the ureter and cutting between the clamps. A No. 2 chromic suture is slipped over the lower end of this suture and then approximated and brought out of the wound. The kidney is now ready for delivery and it is usually easy to make a lower pole delivery, as I am doing here. This kidney is rather large and I am slowly delivering it as you would the head of a child, through the perineum, taking care to deliver it so that it does not rupture and spread around the contents of this diseased organ.

The kidney is now completely delivered, the ureter is free, and all that is left is the renal artery and vein. I place two gall-bladder clamps on them. These I find much better than ordinary clamps, as they are more delicate and do not take in such a wide area of tissue. They are easier to remove and entirely satisfactory in clamping off these vessels. I now cut the kidney free of its blood-supply and get it out of the way. This leaves a nice cavity in which I can work. A plain curved needle is now threaded with No. 2 chromic gut and I make a tie ligature for the artery and vein. This is the only safe method to handle these vessels. A tie that is put on before the kidney is removed or simply tied around the large stump is very unsafe. The fat is cut through, the catgut gets wet and expands, so that many of these ligatures slip and serious and fatal bleeding occurs. The clamps are now released and the ligatures secured. If any bleeding points are noticed, they are easily picked up and another suture is placed through the renal stump. You see this large cavity which is left. In this I place a cigarette drain for a few days. I am closing the deep fascia with chromic gut and the skin with silkworm-gut and clips.

I have asked Dr. Blackford to examine this kidney for us, and he reports that it was saccular, and lobulated. It measured

8 inches in length and 4 inches across. A longitudinal section shows very little kidney tissue and that in the lower pole (Fig. 427). You see some of the cavities of this kidney contain turbid

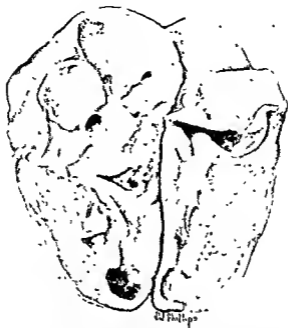

Fig. 427 — This is the kidney removed. The large cavity in the upper pole will be noted with its thick cyst-like wall. The small portion of renal tissue will be noticed in the lower pole.

urine. They are lined with a creamy membrane. There is no evidence of tuberculosis. The diagnosis is hydropyelonephrosis.

ADENOFIBROMA OF THE PROSTATE, WITH PRISMATIC VESICLE CALCULI

Necessity of Complete Survey of Prostatic Patients. The Comparative Frequency of Urinary Stones with Prostatic Obstruction.

THE third case this morning is a patient of sixty-one years, who is suffering with urinary retention due to adenofibroma of the prostate. His admitting complaint was frequency of urination, chiefly during the day, the urinary stream constantly getting smaller, and a substantial loss in weight.

There was nothing of particular interest in his social, family, or past medical history. His illness dates back one year, during which time he has been arising at night to empty his bladder. The past five months he has had increased urinary frequency during the day, and states that the act is both painful and difficult. The stream has never been cut off completely, and he has never resorted to the catheter. He underwent a course of prostatic massage without relieving the symptoms. He further states that the urine has been turbid in appearance, but no bleeding. There has been no pain in the bladder itself, and the urine has never shut off suddenly.

Examination.—This patient is fairly well nourished. The urine has been examined and shows a light trace of albumin, no casts, considerable number of red corpuscles, two to ten pus cells to a field, and many Gram-positive cocci, resembling staphylococci. It has been my experience that long-standing staphylococcal infection of the urinary tract either in the bladder or in the kidney frequently produces calculi; so, whenever I find this occurrence, I make an extra careful search for a calculus. This is a clinical point well worth remembering. The presence of red blood-corpuscles is also suggestive of calculus.

With a Coude catheter I obtained 100 c.c. of cloudy urine. I refrained from cystoscopy this patient because of the small

urethra and an acute angulation produced in the prostate by the enlarged fibroma of the middle lobe. This brings up another point in the examinations of prostates which I think is important. Cystoscopy is an extremely important operation and it gives us knowledge that cannot be obtained in any other manner. But there are a few patients who have urinary lesions, in whom I do not employ it. However, I always consider carefully the caliber of the prostatic urethra, the amount of retention, and the course of the distorted urethra through the enlarged prostatic channel. Preferably I use a No. 18 caliber cystoscope, as this is much smaller than the standard No. 24. It must be remembered there is considerable deformity produced in the prostatic urethra, so that the introduction of the cystoscope into these bladders is not always easy, and at times impossible without producing grave injury, and it is frankly wrong to force a straight tube blindly through an obstruction.

I mention this because I have seen two accidents occur in this type of case: one in which a large cystoscope was forced into a bladder and the patient died in eighteen hours with a urethral chill and a temperature of 106° F. This accident was a great shock to the urologist as well as the family. The second was a case where the cystoscope was forced into the rectum. This patient recovered. I simply want to bring up the point that not all patients can be cystoscoped, and it should not be insisted upon in the face of serious obstruction.

I felt that this patient was one of the type who should not be so examined. The next step in the examination was to have the bladders, ureters, and kidneys x-rayed. This should be done routinely in all prostatitics, for it is a very common occurrence to have urinary calculus in these cases of chronic prostatic obstruction, and many of them are overlooked. They are probably produced by the presence of back pressure, urinary stasis, and urinary infection. In spite of the lack of vesicular irritation in this patient, we found four large prismatic calculi in the bladder, the x-ray of which I am showing you (Fig. 428).

This patient's heart has been gone over and found to be in good condition, his blood-pressure is, systolic 135, diastolic 50;

his Wassermann is negative, and his blood chemistry is normal. The urea nitrogen is 23 mm. per 100 c.c. of blood, and the creatinin content is 1.5 mm. per 100 c.c. of blood. Blood-chemistry has given us a wonderful advantage in handling the surgical treatment of prostatism. Twenty years ago this condition was considered a surgical problem only, and the mor-

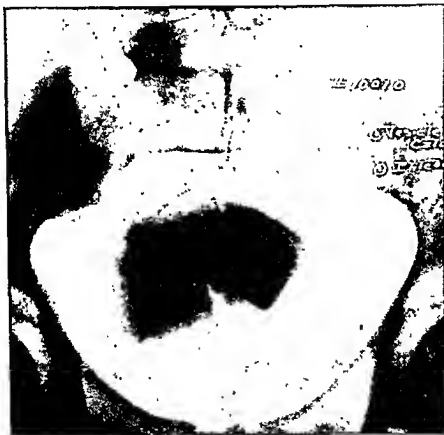


Fig. 42S.—This is an x-ray of the pelvis showing the peculiar angular vesicle calculi with a number of small calcified glands.

tality of the operation was 40 per cent. It is now recognized that the handling of these patients is as much the work of the internist as it is of the surgeon.

These patients are rarely emergency cases, except for relieving an overdistended bladder, and the question of whether or not to operate and when to operate can be arrived at in a leisurely

manner. A careful study must be made of the blood-pressure and the condition of the heart. The lungs should be gone over. The intestinal tract should be digesting and eliminating normally, for many of these patients are suffering from a low-grade toxemia from a chronic nephritis. Most important of all should the blood-chemistry be estimated and the renal function determined. The most reliable is the phthalein test, preferably given intravenously, and the operation should rarely be undertaken if there is less than 30 per cent. for the first two hours.

The ordinary urinalysis is often deceiving and very misleading. How many patients have shown urine of low specific gravity, perfectly clear, free of albumin, sugar and casts, and thought to be good renal risks! On them a cystostomy was performed, or a prostatectomy, and within seventy-two hours the patient was dead of renal suppression and acute nephritis! In other words, we may have a negative urine and yet have badly damaged kidneys. How is this to be estimated? The blood chemistry will usually give us the warning. The normal urea nitrogen is 15 to 20 mm. Should it rise over 30 or 40 mm. we should know it is a sign of danger. The normal creatinin content is 1.12 mm per 100 c c of blood. If it rises again above 2.5 or 3 mm., proceed with caution. In other words, there is a blood retention of these salts, showing a renal insufficiency. As Hugh Cabot said:

"I can easily take a clever young surgeon and within six months teach him to do a skilful prostatectomy, but it would take six years to teach him to handle these prostatics with real judgment."

The fine art of good judgment, careful management of prostatism, both medical and surgical, is not the operation itself, but the combining preoperative care and conditioning of the patient, equalizing the renal balance, and after the bladder has been relieved, bring up the function to normal, which sometimes takes three or four months, the performing of a skilful operation and the very careful handling afterward.

We have weighed all these considerations in this patient and have deemed him a fit subject for prostatectomy. My assistant

has inserted a metal catheter and filled the bladder with boric solution, as is my custom. I have elected the suprapubic route on account of the calculi and the size of the gland. Dr Anderson is giving the nitrous oxid gas, with a very small amount of ether. He gives this very skilfully and it has proved a most satisfactory anesthesia. I have incised the skin and fascia. There is no bleeding, as you see, and with the introduction of the self-retaining retractors the well-distended bladder bulges

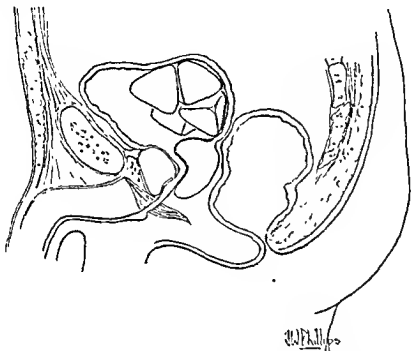


Fig 429.—This is a diagram of the angulation of the urethra through the prostate and of the position and relative size of the calculi.

slightly into the lower part of the wound. The peritoneum is gently pushed back with gauze, and, as in the other case, I pick a place in the bladder walls free of veins. I make a puncture in the bladder with a sharp-pointed scalpel, my assistant now takes hold of the edges of the bladder with curved forceps. I prefer these to the Allis, which often, with their sharp edges, cut and tear the bladder or the surgeon's gloves. I now empty the bladder with the tonsil aspirator, and as I spread the bladder edges you see these white calculi very plainly. They are easily lifted out.

You will notice their peculiar shape, one being prismatic, the other three almost perfect isosceles (Fig 430) They are most unusually shaped calculi and it is difficult to figure out just how they are formed Vesicle calculi are invariably round or flattened and do not have sharp edges These resemble pieces of used billiard chalk

My left index-finger is now introduced into the rectum to give me an idea of the thickness of the capsule and to lift up the prostate for the enucleating finger of the right hand. I am now forcing my finger into the prostatic urethra which splits the capsule and gives me my line of cleavage This is shelling out very easily, and I am removing both left and right lobes in one mass It is now free all around, and with these curved sponge forceps I





Fig 430—This is to give an idea of the peculiar prismatic and angular formation of these calculi Three of them were almost perfect isosceles

easily lift it out of the bladder I now place the bladder retractor within the viscus to search for any bleeding points As I pointed out in my previous case, the two major sources of bleeding are the large vessels on the bladder wall and the vessels in the prostatic capsule, so we make sure before closing that there is no leakage here This prostatic cavity is also packed very tightly with 2-inch gauze, and carefully palpated with my finger to see that the gauze actually goes within the capsule and not in the bladder, which I am sure frequently happens Everything is now dry This 3-inch fenestrated drainage-tube is now placed in the bladder, and the walls are sewn as tightly as possible with No. 2 chromic catgut A cigarette drain is placed in the pre-vesicle space and the fascia united with a continued suture.

Two silkworm through-and-through sutures are inserted, the skin incision itself being approximated with skin clips. This makes a very nice closure and the silkworm-gut is now tied over.

Dr. Anderson will show you that the patient is very slightly under the anesthetic and responds to questions put to him, although in a dopey manner. His pulse is good, having lost very little blood, and the operation taking only a comparatively few minutes.



DIVERTICULUM OF THE URETHRA CONTAINING A LARGE CALCULUS. FREQUENCY OF DIVERTICULI IN THE PROSTATIC URETHRA. TENDENCY TOWARD CALCULUS FORMATION IN THE PRESENCE OF STAPHYLOCOCCUS ALBUS. DIAGNOSIS AND OPERATION

THE existence of diverticuli of the urethra is more frequent than is generally known, and only by the use of the modern cystourethroscope have they been discovered. We note the same experience with diverticuli of the bladder. Few of these were reported until a comparatively short time ago, when the far more universal use of the cystoscope demonstrated the presence of these sacculations. They are not considered rare as they once were, and a large series have been reported by Drs. Hinman, Kretschmer, Lewis, Young, and other urologists.

Due to the peculiar contraction and small caliber of the posterior urethra, this portion of the urologic tract has been overlooked, and in my opinion a number of anomalies missed. That portion of the posterior urethra which is bounded by the outer and inner contracting bands of the compressor urethral muscle, commonly called the sphincter, is the portion which interests us this morning. Here we have a verumontanum and ejaculatory ducts as the main anatomic features. There are some normal irregularities in these strictures, and it is difficult to say just what constitutes pathology. However, we do find in this location distinct cavities, bands, greatly dilated ducts of the seminal vesicles, and diverticuli. I have had in my own practice about six of these latter, most of them being $\frac{1}{2}$ to 1 cm. across and 1 to 2 cm. in depth.

They give some of the symptoms complained of in chronic prostatitis and vesiculitis: quite cloudy urine, a dull aching or itching in the prostatic region, with frequent urination. The symptoms are rarely acute, but annoying and distressing to the patient. They are probably congenital in origin and other defects should be looked for in the urinary tracts.

The treatment of them is difficult. Surgery so far has offered little to help them. The treatment to date has consisted in sterilizing them of bacteria and cleaning these cavities as best we could. Very few of these urethral diverticuli have been reported and many standard text-books on urology do not even mention them. They also occur in women. Last spring I found one of these diverticula in a young woman who had a chronic urethritis. On milking the urethra I emptied out 3 c.c. of stale urine. A urethrogram showed a diverticulum the size of a large green olive. I operated on this case for Dr. Clancy. The method of attack was to cut down upon it from the anterior vaginal wall, carefully dissecting it out. A catheter was put into the bladder and the vaginal incision closed tight. She made a good recovery and has a clean urethra today.

The case this morning is particularly interesting on account of the patient's past history. He is a young man of thirty-six years, who has always been athletic and apparently in good health. About twelve years ago he was operated on by Dr. James B. Eagleson of this city for an irritation of the bladder and abdominal pain. Before the operation the patient had been cystoscoped by Dr. G. S. Peterkin, who found a calculus in the upper portion of the bladder. An x-ray at this time showed a straight pin in the lumen of the appendix, which had penetrated the bladder wall, and on the portion of the pin within the bladder cavity the calculus was formed. There was also a calculus formation around the portion of the pin within the appendix.

There was a question just how to attack this surgical problem. You will notice on his abdomen a large scar in the right inguinal region, also one in the median line above the pubes, both showing evidence of having healed by granulation. An attempt was made to operate intraperitoneally, through an ordinary elongated appendical incision. This, however, did not reach the bladder, so a second incision was made directly over the bladder; the appendix and the bladder wall were then exposed. The appendix with its vesicular calculus and enterolith were removed. The patient made a good recovery after a very prolonged convalescence. He had many chills and sharp rises in temperature.

His wounds opened up and it took him some nine months to get about on his feet again. His urinary tract must have been overloaded with a severe infection which he overcame with great difficulty.

His further history was that he contracted specific urethritis several times, which resulted in a stricture of the urethra. He stated that two years ago he had this stricture cut by an internal urethrotomy. He claims that he has had frequent urination for years, and that the urine has always been cloudy. He has been treated by Dr. Douglas for the past two weeks, who has been washing out the bladder with a catheter and instilling a solution of mercurochrome. Under this treatment he thinks the urine has become a little clearer, and he feels more comfortable. In the mornings there is always a large amount of pus in the urine, and it has a strong odor. Dr. Douglas has been unable to pass a sound, meeting with an obstruction which feels like a stricture.

The principal points of the examination I shall bring out are these: You see he is well nourished, his blood-pressure is systolic 130 mm., diastolic 80 mm., pressure 50 mm. The reflexes are normal, the inguinal lymphatics are large, movable; the Wassermann is negative, there is no pathology in the chest, the meatus is dry, the urine is very cloudy, specific gravity 1022, trace of albumin, no sugar, acid. Microscopically it shows numerous pus cells, considerable number of scattered extracellular Gram-positive cocci, many irregular Gram-negative and positive rod-shaped bacilli, occasional red blood-cells, no tubercle bacilli. The prostate is three fingers wide, smooth, soft, and boggy. The vesicles are apparently normal. There is a hard mass anterior to the left vesicle, which has a sharp edge, large, and measuring 5 cm. in length and 2 cm. in width. It is stony hard and not movable.

The anterior urethra, when explored by a No. 24 bougie, was negative to the first sphincter. A No. 16 metal catheter, French, was passed into the bladder. In the prostatic urethra grating and crepitus were encountered. I next introduced a No. 18 French Buerger cystoscope into the bladder. The catheterized urine was very cloudy, bladder capacity 90 c.c. Mucous mem-

brane was universally injected, showing scars and bands throughout. The walls were rough and contracted, the trigone was elevated 3 cm above the right ureteral orifice. There was a diverticulum with a slightly oval mouth. This was 3 cm in depth. There were no tumors and no enlargement of the prostate. On drawing the cystoscope into the prostatic urethra, a well-marked

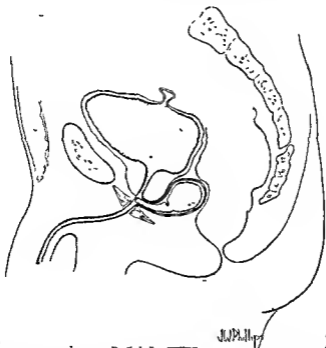


Fig 431 —This is a diagraphic illustration of the diverticulum of the urethra between the prostatic and presser muscles. In it will be seen the calculus with a long neck. In the posterior wall of the bladder will be seen a small diverticulum.

diverticulum was found, slightly at the left of the median line and anterior to the verumontanum. This diverticulum measured 1 by $1\frac{1}{2}$ cm. Projecting out of it were two calculus prongs, slightly dark in color, and a diagnosis was made of diverticulum of the urethra containing a calculus (Fig 431).

Next a No 24 Buerger cystoscope was introduced to get a better view. This was withdrawn and a Young rongeur

cystoscope introduced, to try to get a hold on this calculus and extract it through the urethra. The only result obtained was to break off the projecting prongs. A Young endoscope was next tried. The obturator went to the stone, a grip was secured on it, but no amount of pulling would dislodge it, and further attempts in this direction were given up. Two days later another effort was made in the same manner, as I have been successful in doing this before, but all I obtained was a few pieces of crushed stone. I then decided it was entirely too large to remove through the urethra.

Before proceeding to the operation I would like this opportunity to mention my experience with the *Staphylococcus albus* infection of the urinary tract. Whenever I find this organism I am always suspicious of calculus, whether it be the bladder, ureter, or the kidney. Many a time a patient has walked into the office and the preliminary examination reveals the presence of this staphylococcus. I immediately become suspicious of a urinary stone and will so consider it until I have proved it otherwise.

Long-standing urinary infection means to me, first of all, poor drainage, as we find in the kidney, due to ptosis, kinking, or ureteral stricture. What happens is this: A pool of stale urine will form in one of the calices in a dilated pelvis, a diverticulum of the bladder wall, or in a prostatic pouch. These collections of stale urine in time become infected with colon bacilli or staphylococci. A nucleus is present for the formation of stone. There is a precipitation of urinary salts around the paternal nucleus. These are the classical conditions for the formation of calculi: obstruction, collection of urine, slowing up of the urinary stream, and infection. So remember, whenever you find staphylococcus in the urine, search for a stone.

We have now made a diagnosis, and the next question is, how shall we attack this calculus? Shall we enter the perineum, or shall we open the bladder suprapubically? Demonstrating the calculus to be fairly well distal to the bladder, we place our patient in the lithotomy position and prepare to do a lithotomy. There are many incisions of the perineum, with a view to expos-

ing these deep and rather difficult strictures so as to get at it. I think, however, that the best incision is a slightly curved transverse one, through the skin and fat. This throws the flap backward and we now have plenty of room to carefully dissect out any structure we wish.

I am placing in the urethra a Guyon sound which is used as a guide. You will notice the bulb of the corpora spongiosum. I call your attention to this, as nicking this structure or cutting into it produces a great deal of troublesome bleeding, and a little care at the start will easily avoid this embarrassment. It should be well pushed up out of the way. We now expose the superficial layer of the triangular ligament and cut through this in the median line. This brings us down to the membranous urethra. You see this glistening structure which is about the size of a lead pencil. It contains the sound and we palpate it very easily at this point; there it turns sharply beneath the pubes and enters the bladder.

We now open the urethra and, as I wish to dilate this portion of it, I slip a gauget director into the bladder, and immediately I get a gush of urine. I am now dilating it so as to insert Young's prostatic retractor. This lifts up and brings forward the prostate and vesicles, making the future dissections very much easier. We are now able to see the neck of the calculus (Fig. 432). It is formed in this cavity which is pear-shaped and will not allow its escape, due to the comparatively narrow neck, like that of a vase. I nick this diverticulum with a knife, and am now inserting my index-finger to loosen it up from the wall. I find that it is adherent everywhere to the rough surface of the calculus. It is now free all around, and I introduce a pair of forceps, slipping the blades of it carefully around the calculus as we do the obstetric forceps on the head of a child, gently rocking it from side to side, and slowly extracting it. I shall put it in a dish and pass it around. You see it measures $2\frac{1}{2}$ by 5 cm. It is stained a dark mahogany, it is very rough and consists of a pear-shaped body with a long narrow neck.

The disposition of this diverticulum is very important. Possibly its walls could be loosened and sucked outward, as we

do bladder diverticula. On account of the triangular ligament, however, and the close proximity to the rectal wall I do not deem this advisable. I hope to obliterate the cavity by swabbing it with carbolic acid and alcohol and then packing the same with 2-inch gauze. To drain the bladder I am inserting a No. 24 catheter through the perineum into that cavity. The fascia I

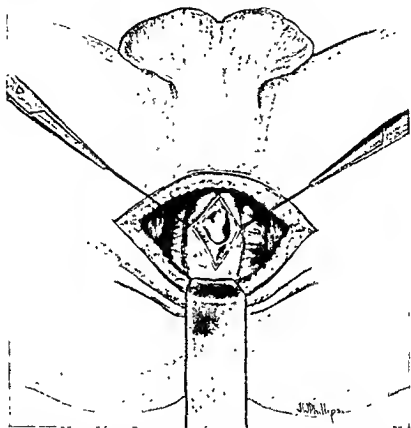


Fig. 432.—This shows the urethra opened and the diverticulum of the urethra exposed. Projecting through the orifice is seen the neck of the calculus and the body of it is just suggested below.

am uniting with a few sutures of No. 2 chromic gut, the skin with silkworm-gut.

Before taking the patient off the table I am always careful to see that the tube draining the bladder is working smoothly, filling the bladder two or three times with a warm solution, making sure that all clots are out and there is no intravesicle bleed-

ing. This is quite important, for frequently these tubes become plugged, fail to drain, and the surgeon is called through the night to reinsert a tube that has been pulled out or become entirely plugged. It will save much trouble to use a sufficiently large tube. Keep it draining by irrigating it every two hours by catheter syringe, and sewing it securely enough to the perineum.

CLINIC OF DR. J EARL ELSE

UNIVERSITY OF OREGON MEDICAL SCHOOL

ATYPICAL TOXIC GOITER

GENTLEMEN, a few years ago a diagnosis of toxic goiter or hyperthyroidism was looked upon as being a diagnosis of an actual pathologic condition. As a result of increased interest and the research work in goiter that has taken place the past few years we now regard the terms toxic goiter, hyperthyroidism, or thyrotoxicosis as general terms covering a number of clinical and pathologic entities. In the clinic this morning I wish to present several types of toxic goiters, and while there are present examples of the two types that are supposed to be most common, namely, exophthalmic goiter and toxic adenoma. I shall pass them by, as I wish to spend the time discussing the atypical types of toxic goiter. First, I want to show you some adolescent girls with goiters that appear to be toxic, I say appear to be toxic, because while these girls have some of the symptoms of hyperthyroidism, they do not have toxic goiters, the symptoms being due to other causes.

The thyroid gland increases in size and ability to secrete thyroxin during the adolescent changes in order that it may meet the demand thrown upon it for more thyroxin. Normally the changes in the thyroid gland are only proportionate to those in the body generally. In a certain percentage of cases, something over 50 per cent. in girls and 30 per cent. in boys, according to the surveys being made in the public schools the thyroid gland, which is able to meet the demands thrown upon it previous to puberty, is not able to secrete the increased amount of thyroxin needed during the adolescent period, and as a result it undergoes abnormal changes which we designate as adolescent goiter.

We have been able to differentiate two different types of adolescent goiter. In the common form there is an oversecretion of colloid. In the other form there is hyperplasia and hypertrophy. As you will recall, the acini of the thyroid have the ability of secreting colloid and thyroxin, the former we believe to be an inert substance whose function it is to act as a reservoir for the thyroxin, holding it in suspension until it is needed. The latter is the active principle.

The thyroid gland is the only gland in the body, with one exception, containing acini which does not have a duct through which to discharge its secretion. The exception to that rule is the pituitary, where a few acini are found.

Thyroxin is secreted by the epithelial cells and then stored up in the colloid within the acini, so that a sufficient amount may be available in case a sudden demand is thrown upon the thyroid for its active principle. Then as the thyroxin is needed it is absorbed from the colloid and deposited either in the blood or lymph-vessels.

In the first group of adolescent goiters referred to the epithelial cells in their attempt to secrete more thyroxin, secrete too much colloid, and hence the acini become distended, increasing the size of the entire gland. The lobes are enlarged, the right usually being larger than the left. In case there has been a rapid secretion of colloid, the thyroid may be quite tense, and the poles, especially the upper, very definitely palpable. In the second group of adolescent goiters the increased demand for a greater secretion of thyroxin results in an increase in the number and size of the epithelial cells, and perhaps in an increase in the number of acini. This hypertrophy and hyperplasia may be diffuse or may be localized. It diffuse, the lobes are increased in size and present a smooth appearance, but if localized the gland may be nodular, giving an impression to the palpating hand similar to that of palpating an adenoma. We know that this nodular condition is due to localized hyperplasia or hypertrophy instead of adenomata because, first, in our early work under the erroneous diagnosis of adenoma we removed some of these, and second, since we found that they

were not adenomas, but localized hyperplasia, we have observed that they will clear up quite uniformly under treatment. Adenomas do appear during the adolescent age, but the majority of the nodular growths seen in the adolescent period are merely localized hyperplastic areas which will completely disappear under treatment.

We have here three girls with adolescent goiters. As our time is limited I shall not present the histories in detail. All of them were born in Oregon. All of them, with the exception of the usual contagious diseases incidental to childhood, have been well. Two are fourteen years of age and one is fifteen. In all three you see a definite enlargement of the thyroid gland. In two of them you see that the neck is perfectly smooth, but in the third one the neck is somewhat nodular. The first two are colloid goiters. The third belongs to the localized hyperplastic type of adolescent goiter. The general physical examination of all three girls shows them to be perfectly normal except for, first, the enlargement of the thyroid, second, a slight fine tremor; third, a tachycardia varying from 90 to 110, and fourth, the girls are somewhat nervous. The basal metabolic rate in these girls is persistently normal. The symptoms that you see here are not rare among the girls of the adolescent age, but in the presence of a persistent normal basal metabolic rate I think we are justified in saying that the enlarged thyroid is not the factor that produces the tachycardia, slight tremor, and nervousness. In fact, it has been our observation that these symptoms occur just as frequently among the girls who do not have adolescent goiters as among the girls who do.

Next I wish to discuss a group of goiters in which I am very much interested, namely, the postadolescent goiter. Some of these patients present nothing abnormal except a variable enlargement of the thyroid gland. There is, however, a considerable group in which we have a mild degree of hyperthyroidism in some of which the symptoms are constant, and there can be no question as to the treatment, namely, the surgical removal of the greater portion of the gland, but in others the symptoms

are transitory. These facts are well brought out with these two cases

This girl is twenty-five years of age, single, occupation physician's assistant. She was born in Wisconsin and has lived in Minneapolis, Chicago, San Francisco, Spokane, and the past fifteen years in Portland. Father living and well. Mother living and well, had a goiter when she lived in Wisconsin. *Four sisters, three of whom have simple goiters.* Health in childhood. Had "bilious attacks," but doesn't have them any more. Menstruation began at fifteen. No evidence of goiter at that time. Previous illnesses: Measles, tonsillitis, and mumps. Operations. Tonsillectomy. When this girl's history was taken in July, 1923, she stated that she did not know when the goiter began, but thought that it was larger at that time than it had ever been before. Appetite was not good. Constipated. Pulse 96, regular, good quality. Systolic blood-pressure 106, diastolic 78. Skin dry, eyes normal. Tonsils enlarged and cryptic, have since been removed. Larynx slightly reddened. Diffuse enlargement of both lobes of thyroid. Neck measured 34 cm. Blowing sound heard in vessels of neck, but none over the thyroid gland. The heart was within the normal borders. Apex-beat was not accentuated. Lungs negative. Abdomen. No abnormal tenderness, no masses palpated. Extremities normal. Reflexes normal, slight tremor present. Basal metabolic rate on November 21, 1923 was plus 37 per cent. The weight at that time was 105 pounds, the pulse-rate lying down was 78. December 2, 1923 the basal metabolic rate was plus 2 per cent, weight 110 pounds, pulse-rate lying down 72. The neck measured 32 cm. Both lobes showed some enlargement, were firm, isthmus was palpable. Pupils reacted normally to light and accommodation. No abnormal eye signs present. Heart normal. Physical examination otherwise negative. Blood-pressure, systolic 103, diastolic 73. At the present time you will notice that there is no evidence of goiter, and upon palpation the thyroid is found to be perfectly normal in size. The pulse-rate was 72, other physical examination is negative.

Now as to what the final outcome is going to be I cannot say. I believe, however, that this girl is cured of her goiter. She did not have a common toxic hyperplastic goiter, but did instead have an unstable thyroid gland which at times was *oversecreting and at times undersecreting.* Under treatment her thyroid has become stabilized. In this group of cases we usually advise the patient to take the usual prophylactic dose of iodine, namely, 10 mg per week, or use the iodine-containing salt in place of the ordinary table salt.

The next patient belongs to this same group, but has a different type of goiter. At present she is twenty-nine years of age. She was first seen seven

years ago. At that time she had a small goiter. Two years ago, or five years after the first examination, she came in complaining of goiter, nervousness, and tachycardia. She was single, occupation teacher. Family history: Father sixty-three, living and well. Mother died at fifty-two, nephritis. Two brothers living, no goiter. Sister living, small goiter. Personal history: Previous illnesses, influenza. Menstruation always painful. Operations, tonsillectomy and dilatation of the cervix for painful menstruation, which gave only temporary relief. Present illness: Goiter had been present since puberty, remaining small until 1921, when it began to increase in size. Noticed an increase in the size of the gland with each menstruation and she gradually became more nervous. Her appetite was very good, but she did not gain in weight. Bowels regular and she slept well.

Physical examination showed her to be well built, well nourished, pulse 104 and regular. Temperature normal. Systolic blood-pressure 140, diastolic 70. Eyes normal, no evidence of exophthalmos. Tonsils have been removed. Diffuse enlargement of both lobes of the thyroid gland, the right being a little larger than the left, surface smooth. Lungs normal. Heart normal except for systolic murmurs at the base. Nervous deep reflexes normal, slight tremor. Basal metabolic rate, May 29, 1922, plus 30 per cent. August 8, 1922, plus 32 per cent.

Because of the persistent rise of the basal metabolic rate, the persistent increase in the nervous condition, tachycardia, and hypertension, together with the presence of goiter which had increased in size since the preceding year, we believed that this case did not belong to the same group as the patient I have just shown you under the diagnosis of transitory hyperplastic goiter of the postadolescent period, but was a definite toxic lesion which should be operated upon. Accordingly, a subtotal double lobectomy was done. The section of the gland showed large masses of colloid, and in many places a new formation of acini within the old acini, giving the picture described by Wilson in an early paper as compensatory hyperplasia. The epithelium surrounding the large colloid acini was flattened. Diagnosis, compensatory hyperplasia.

This case teaches a valuable lesson. The large acini distended with colloid and lined with flattened epithelium are the mute evidence that there has been a period of hyperthyroidism. In order to overcome this the new acini have been formed within the old acini. This gave the needed increase in thyroxin secretion, but the process did not stop when the need was met, but continued until there was an oversecretion giving the tachy-

cardia, nervousness, tremor, hypertension and rise in the basal metabolic rate. In the light of what we have observed, we believe first that this girl's goiter could have been prevented by giving the prophylactic dose of iodine before it developed. We advise 10 mg of iodine per week from eight years of age to eighteen. Second, had she been treated after it developed, she could have been cured. For this we find desiccated thyroid more efficient than iodine, and third, in the light of our more recent experience, had we treated her when we saw her five years ago it could still have been cured and the operation would not have been necessary. When we saw her two years ago it was too late for medical treatment.

At the present time this patient has a basal metabolic rate of minus 8 per cent, which is within the normal limit, the normal being between minus 10 and plus 10 per cent. She feels perfectly well, is no longer nervous, and her pulse-rate is normal.

We have seen quite a group of these postadolescent mildly toxic goiters. The majority of them we have placed in the type diagnosed as transitory. Of the persistent toxic type we have seen, in addition to the compensatory hyperplastic type that you have seen today, definite hyperplasia, which in the course of time we believe would have developed into the typical findings of the exophthalmic group. In addition to these there are, of course, the usual types of toxic goiters, namely, the exophthalmic and toxic adenomata occurring at this age, but, as we are discussing the atypical toxic goiters, I have not included them.

The next condition that I wish to discuss is that of adenomatosis, and in presenting it I wish to call your attention to two definite pathologic pictures which have been described in the literature as independent pathologic processes, but which, as the result of our study, we believe to be the early stages of the same lesions. You are undoubtedly familiar, either through your own investigation or in perusing the literature, with this picture (Fig 433). This is, as you will perceive from the slide thrown on the screen, a new growth of actini, diffuse in its nature, without any attempt at the formation of a capsule. The reason for a lack of the capsule is easily understood. The connective

tissue forming the capsule of a tumor is not a part of the new growth, but is instead connective tissue which has been pushed ahead of the tumor growth as it developed. The adenoma of the thyroid gland, as adenomata elsewhere, springs from a definite point, grows from that point, and as it grows the parenchymatous tissue is destroyed by pressure necrosis, while the more resistant connective tissue is pushed ahead of the new growth and forms a capsule for it. In adenomatosis the acini develops simultaneously from various localities, and hence there is no at-



Fig. 433 —Adenomatosis, early. Section made from a diffuse enlargement of the thyroid gland. Both fetal acini and adult or colloid-containing acini are present.

tempt at capsule formation. You see here fetal acini presenting exactly the same appearance as do the acini of the thyroid gland of the fetus. Over here you see adult acini of the same type seen in a normal thyroid gland from an adult. Between these two are all gradations. Were you to see this slide without knowing anything of the structure from which it came, you would make a diagnosis of a mixed adenoma because the appearance is the same as that of the adenoma in which some of the acini have taken on the power of secreting colloid, while others still retain the

fetal type This, however, as I stated, was a diffuse growth not encapsulated, thus making for us the diagnosis of adenomatosis. The specimen being passed around is the gland from which the section was taken that is being projected on the screen.

This specimen (Figs 434, 435) which I hold in my hand presents upon first glance an entirely different appearance from the one from which the slide was made As we study this specimen more closely, however, we discover that while there are certain

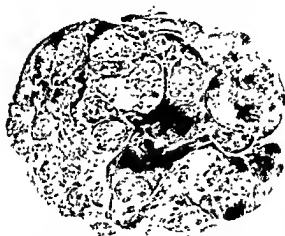


Fig 434—Adenomatosis, advanced The acini are filled with colloid and segregated more or less in groups Some of the acini have been separated for the purpose of demonstration, causing them to present a more nodular appearance than normal

colloid masses that can be fairly easily separated from other masses of the same type, these portions which we separate are masses and not tumors In other words, we have in this mass that I have now separated from the gland a group of colloid acini that are not encapsulated The term "adult adenoma" has been wrongly given to this type of thyroid gland I say wrongly given, because, as you have just seen, these are not encapsulated masses, and to be an adenoma they must be encapsulated There undoubtedly has been a new formation of acini, but which have

developed in a diffuse manner, and hence not according to our ideas of tumor formation. In the course of time the newly formed acini take on the function of secreting colloid and often thyroxin. In the late stage there is an overproduction of colloid and a sequestration of groups of acini, as was described by Wilson in one of his early communications. The size of the thyroid in cases of adenomatosis varies greatly. In some of the early cases there is but little enlargement, while in some of the late cases there is an enormous enlargement. In fact, some



Fig. 435—Adenomatosis, advanced. The acini are distended with colloid and present very definite groups, which can be separated the same as those shown in Fig. 434.

of the largest thyroid glands that we have seen belong to this group.

Clinically the symptomatology does not vary materially from that seen in the ordinary toxic adenoma. These two patients will serve as illustrations.

1 Female, aged forty-three, married, nurse, white. Father died of carcinoma of stomach. Mother dead, tumor, the nature of which she does not know. Three brothers living and well. Four sisters living and well. Husband living and well. Three children, all well. One brother had a goiter. Menstrual: Patient began at fourteen, but during past year has been menstruating every two weeks and lasting six days. The amount is profuse. Previous

illness Influenza a few years ago, eighteen months ago had an indefinitely described illness accompanied by chills, irregular temperature running as high as 104° F. Was constipated and in bed two months. Fourteen years ago had double salpingectomy. Present complaint Palpitation of the heart, nervousness. Present illness Palpitation of heart began with illness eighteen months ago and is steadily getting worse. Appetite variable. Bowels good. Physical examination Present weight 152 pounds, former weight 160, pulse 96 and regular. Blood-pressure, systolic 118, diastolic 68. Pupils react to light and accommodation, no abnormal eye signs. Teeth have all been removed. Thyroid, diffuse enlargement of both lobes, neck measuring 36.2 cm. Patient complains of some tenderness over the isthmus. Lymph-glands, few small cervical glands palpable, otherwise normal. Heart, heaving impulse at apex producing movement of entire breast. Point of maximum intensity fifth interspace, 12½ cm. from the midline. Systolic murmur heard over the entire precordium. Abdomen, diffuse tenderness over abdomen, most marked in center of epigastrium, scar from the former operation in midline below navel. Genitalia, uterus enlarged and slightly nodular. Nervous, deep reflexes exaggerated, tremor. Basal metabolic rate plus 30 per cent.

The patient was very nervous and her general physical condition did not appear any too good, so, in spite of the fact that the metabolic rate was only plus 30 per cent, the superior poles were both ligated under local anesthesia, and four weeks later a subtotal double lobectomy was done. The pathologic report of the specimen removed was as follows. Gross appearance, two ovoid masses of thyroid totaling 53 grams. The external surfaces were rather irregular from bulging cystic areas. On section there were many cystic areas. The tissues between these was rather pale, compact, and firm. A microscopic examination. The acini vary in size from minute apparently new formed acini to the large cystic type. Many of the acini contain colloid. There are areas of compact epithelial tissue where localized hyperplasia had occurred resembling to some extent fetal adenomata. There is some round-cell infiltration and some increase in interstitial connective tissue. Diagnosis, adenomatosis.

2 The next patient is a woman, white, fifty-one years of age, married. Occupation housewife. Father and mother both dead, one of organic heart disease and the other of pneumonia. Two brothers living and well. One sister living, three dead, two of which had goiter. Husband and four children living and well. Previous illness Measles, influenza, mumps, and whooping-cough. Complaint Goiter, nervousness, palpitation, tires easily, shortness of breath, indefinite pain in back and right hip and thigh. Present ill-

ness. First noticed goiter about fifteen years ago, but had been having palpitation of heart for at least five years before that. Does not know how long she has been nervous, but nervousness is increasing. Has not lost weight, appetite is good, and bowels regular. Menstrual periods irregular, intervals varying greatly. Believes that she is going through the menopause.

Physical examination: Pulse 84, regular. Moderate build, increase in subcutaneous fat. Patient is quite nervous. Blood-pressure, systolic 160, diastolic 90. Eyes react to light and accommodation, no exophthalmos. Teeth have all been removed, wears a plate. Tonsils normal. Thyroid, both lobes enlarged, right lobe more marked than left. Surface smooth, moderate consistency. Heart and lungs normal. Veins of both legs somewhat enlarged, wears elastic bandage. Thinks her legs would swell if she didn't wear the bandage. Basal metabolic rate, December 8, 1923 was plus 41. February 2, 1924 was plus 25 per cent, March 8, 1924 plus 26 per cent. Wassermann negative. Diagnosis, adenomatosis.

Operation, low collar incision, muscles separated in midline, subtotal double lobectomy, skin closed with three subcutaneous catgut sutures and skin clips, drain in center.

The second specimen that I showed you, the one with the large colloid masses, was removed from this patient. At present she feels well and looks well as you see. Immediately following the operation, although we followed the technic I shall show you later, staying away from the recurrent laryngeal nerves, she had a paralysis of the right vocal cord and could speak only in a whisper. Now, as you have heard, she uses her vocal cords, but her voice is not normal. It is steadily improving, and Dr. Jones reports that while the right vocal cord still lags, it is functioning better and will eventually return to normal. The cause of this, we believe, to be due to an inflammatory induration of the nerve following the operation.

These two conditions, while presenting somewhat different pathologic specimens, we believe belong to the same type of goiter, the one in the early stage, the other the late stage of adenomatosis.

Another group of toxic goiter which I wish to discuss this morning may be referred to as atypical hyperplastic goiter or atypical exophthalmic goiter. Practically every physician in the Pacific Northwest is familiar with the picture of the classical exophthalmic goiter. It begins rather rapidly often following some sudden strain thrown on the thyroid gland, such as in acute

illness, physical or nervous shock from an accident, bad news, sudden fright, or overwork. An example of the latter condition was seen in the recent case of a telephone employee who carried a large portion of the responsibility of changing some of the telephone stations from the manual to the automatic without interruption of service. In acute illness we have actually seen more cases of exophthalmic goiter dating the onset to the influenza epidemic than we saw cases of empyema from that epidemic. A short time ago we had one patient who dated the onset to the sudden death of a friend. These cases develop comparatively rapidly, so that within the course of a few months the majority have passed through the stage of maximum intensity. If the cases are not treated or improperly treated, most of them pass into the stage of retrogression and then into the stage of remission, where they are often regarded erroneously as cured. I say erroneously, for if these cases are followed through a period of years it usually recurs. The recurrence may be delayed ten, fifteen, twenty, or twenty-five years. We shall speak of these cases later under one of the other headings of atypical exophthalmic goiter.

Let me say before speaking further that the term "atypical exophthalmic goiter" is more or less of a misnomer, but I am using it to differentiate a variety of cases from the usual classical picture. The first group that I want to refer to may be termed "mild exophthalmic goiter." In this group there is only a moderate overproduction of thyroxin and the symptoms are mild, the tremor is slight, the tachycardia is not marked, palpitation may or may not be annoying to the patient. There is no exophthalmos. The appetite is usually good and often increases, while the weight remains practically stationary. The patients are often more active mentally and physically and sometimes can actually accomplish more than formerly.

We have had one boy under observation that we believe belonged to this type, who passed from a very mediocre pupil in the public school to one of the brightest, skipping an entire grade. Regarding the matter of treatment of this mild type, we are not prepared to say. The majority will clear up with rest, regulation of diet, and hygienic conditions. Whether there will

be a recurrence in later years, as is usually the case with improperly treated more severe cases of exophthalmic goiter, we cannot say.

In contrast with this first group is the acute fulminating exophthalmic goiter. The onset is exceedingly rapid. Within a few days' time or, at the most, a few weeks' time the symptoms become very pronounced and the situation grave. The patient loses weight rapidly. Gastro-intestinal disturbances, the so-called gastro-intestinal crises, are usually present. The patient may be unable to take food or unable to retain it if she does eat. Diarrhea accompanies the gastric disturbance. The pulse-rate may be 140, 150, or 180. The heart may fibrillate and is often dilated. Mental disturbance is pronounced, and sometimes, as in one case we saw, the patient was virtually insane. The prognosis of these cases is very grave. Plummer recently suggested the use of iodine. Since his suggestion we have seen but one case in this group. Iodine given in the doses he recommended produced absolutely no result. The patient went down and died within a few days.

Our routine has been to put these patients at absolute rest, put an ice-collar about the neck, give morphine hypodermically, or chloral by rectum to control the nervous condition. Digalin intermuscularly for the heart if the patient cannot take digitalis by mouth, and then wait a few days for the symptoms to subside sufficiently to ligate the superior pole. If the symptoms do not subside, x-ray therapy is used.

In all but one of the instances referred to this procedure has succeeded. The second pole is ligated in about two weeks and later a subtotal double lobectomy may be done with satisfactory results.

The third group of cases to which I refer are the patients seen in the stage of remission. Since the primary attack there may have been other definite attacks or mild unrecognized attacks or a low grade of continuous hyperthyroidism. During this stage the patients may show some of the symptoms of exophthalmic goiter, such as palpitation, tremor, and exophthalmos. There is usually a hypertension which sometimes is quite

pronounced. The weight may be normal or the patient may even gain in weight. The basal metabolic rate is usually normal, occasionally subnormal, or perhaps at times lightly raised. The general physical condition is usually good. Some of the patients are somewhat irritable. We believe that these symptoms are the result of permanent lesions produced during the attack. We believe that an excessive secretion of thyroxin acting over a considerable period of time will produce definite permanent changes in the heart muscle, in the control of the nervous system, posterior to the eyeball or elsewhere. After the patient's thyroid secretion has become normal these symptoms persist because of the permanent lesions. I have seen patients in whom the thyroid gland has undergone so much degeneration that the patients have become hyperthyroids. In one instance the basal metabolic rate was as low as minus 27 per cent. and yet the patient showed a definite tachycardia, a definite irritability, a definite tremor because of the lesions produced during the period of hyperthyroidism.

Some authors have referred to this condition as disthyroidism or mixed hyperthyroidism and myxedema. I may be wrong, but I do not believe it is anything of the kind. I believe that it is merely a case of persistent symptoms caused by permanent irremedial lesions with the development of myxedema later from overdestruction of the thyroid gland in the reconstruction process. Goodpasture and Fahr have both shown that thyroxin produces definite changes in the heart muscle in the human, and Hashimoto has shown the same thing in his experimental work on animals. If this be true, the cardiac changes and their resulting clinical manifestations, the nervous state and the tremor accompanied by a practically normal basal metabolic rate, indicated that the patients are still suffering from effect of the former attack of acute hyperthyroidism, and they may even become hyperthyroids because of thyroid destruction.

The examination of the thyroid gland of these cases shows a very atypical appearance. There may be areas showing a definite compensatory hyperplasia, while other areas may show a picture of an adenomatosis. Calcareous deposit is common.

Connective tissue is increased and solitary lymph-follicles may be found. We have seen many of these cases, but do not regard them as being a different type of hyperthyroidism, but instead as neglected cases; one author has reported a series of cases which were treated by what he called scientific neglect. In later years he will be able to describe the picture that I have referred to as part of the clinical manifestation in the cases so treated. The following case report and specimen illustrates well the condition that I have described:

This patient is a woman forty-six years of age, married. Father died at fifty-six years of age of apoplexy. Mother at sixty-eight, exact nature of ailment not known, but the patient states that the heart, liver, and stomach were all effected. Her mother had a goiter. Four sisters have goiters, two of which are toxic. As a child she had considerable intestinal disturbance. Began menstruating when she was thirteen, regular and not painful, somewhat scanty. Has always lived in the Great Lakes region or on the Pacific Coast. Tonsils removed three years before patient came to us. Complaint, goiter. Had first attack of acute hyperthyroidism at twenty-two years of age and the next at twenty-seven. Two years before we saw her she had an attack of what she described as exhaustion accompanied by palpitation, but she thinks there was no tachycardia. Since that time she has been having attacks at intervals. She had a marked attack shortly before we saw her. Patient reports that appetite is good and there has been no loss of weight. Bowels are regular. No urinary disturbance except during an attack when she would occasionally have to urinate during the night. Two years before we saw her she had noticed some enlargement of some of the distal phalangeal joints of the hand. No pain in connection with the joints of the fingers, but she has had a little pain in the right elbow. Pulse was 72. Systolic blood-pressure was 140, diastolic 80. Previously it had been systolic 170, diastolic 90. Weight 149 pounds. No exophthalmos. Tonsils have been removed. The thyroid showed a diffuse enlargement with some small nodules. In the first examination there was a musical murmur over the outer border of the right lobe and a bruit over the left lobe. Two weeks later the musical murmur, while not distinct, could still be heard when the patient was lying down, but was entirely absent when the patient sat up. The bruit over the left lobe could not be produced. The lungs were negative, the heart slightly enlarged, and a slight tremor present. The basal metabolic rate was at one time plus 19 per cent. and another time was plus 13 per cent. A subtotal double lobectomy was done. The specimen was somewhat nodular and on cut section it presented a lobulated appearance. There was one cyst present. Microscopic examination showed the acini to vary in size, some being fetal in type, but most of them contained colloid. There was considerable connective tissue present with compressed acini within the connective-tissue masses in places. Solitary lymph-follicles were found. Diagnosis of adeno-

matosis occurring in a gland which had previously been hyperplastic was made. At present the patient looks well and states that she feels better than she has for years.

There is another type of atypical hyperthyroidism which I wish to discuss. These cases are rare, so that I will not be able to show a patient, but will give you the history of a patient we saw a few months ago.

This patient was a man, white, fifty-three years of age, single, laborer. His father died at seventy-five and his mother at seventy, cause unknown. Has two brothers living and well, one fifty-seven and one fifty-one. One sister dead following confinement. No goiter history in the family so far as he knows. Previous illnesses: Measles, typhoid twice, rheumatism in knees and thighs, gonorrhoea ten or twelve years ago, and denied having had syphilis. Has had one toe removed, probably osteomyelitis. The patient states the trouble began two or three months before seen with backache and shortness of breath on exertion. He stopped work, but backache continued. It was worse when he moved. Has tachycardia and palpitation. Some pain in the region of the heart. He has noticed that the heart misses beats, especially on exertion. Physical examination: Pulse 78, irregular. Weight 140 pounds, height 5 feet, 11 inches. Temperature normal. Systolic blood-pressure 130, diastolic 70. Nourishment fair. Eyes react to light and accommodation, with no abnormal eye signs. Teeth unclean and show decay. Throat slightly hyperemic. Thyroid barely palpable. Skin, slight rash on chest and left temple. Lungs normal. Heart, point of maximum intensity sixth interspace and 10 cm. from the midline. Heart-beat could be heard all over the chest, but no murmurs were present. Abdomen showed visible pulsation, otherwise negative. Extremities negative. Reflexes normal. Wassermann negative. Blood normal. Basal metabolic rate plus 43 per cent.

Owing to the atypical history and findings a double ligation of both superior poles was done as a diagnostic measure. Following this the patient showed definite improvement and the basal metabolic rate decreased. A subtotal double lobectomy was done. The thyroid was found to be somewhat smaller than normal, very firm, and cut with resistance. Cut section presented a dense appearance lacking the usual semitranslucent appearance. The gross specimen suggested that there was probably an increase in the connective tissue and a decrease in the amount of colloid. This condition, as I stated before, is rare. I have never seen it present in a patient under fifty years of age. Following the operation the patient showed a definite improvement.

The patient we have for operation this morning is a girl twenty-one years of age, single, occupation telephone operator. Family history is negative for goiter. Menstruation began at fourteen, regular, with some pain three or four hours after flow starts, duration five days, amount profuse. Previous illnesses: Measles, whooping-cough, smallpox. Complaint: When she came to us some few weeks ago she complained of a goiter, nervousness, and tired easily, loss of weight, palpitation and pain in the lower right quadrant of the abdomen. Present illness: She first noticed the goiter at puberty and was somewhat nervous when she was fifteen. During the past year and a half nervousness has increased. Faints easily. She has had pain in the lower right quadrant for some time. Is constipated and the bowels will move only upon taking medicine. There has never been any nausea connected with the pain in the lower right quadrant. Sleeps poorly, but formerly slept well. Her appetite is good, but in spite of this she is losing weight. Physical examination shows her to be fairly well nourished, pulse 78, regular. Eyes normal. There is a diffuse enlargement of the thyroid gland involving both lobes, the right lobe being slightly larger than the left, the isthmus is palpable. Her neck measures 39 cm. The lymphatic glands are normal. The heart is normal. The abdomen shows tenderness in the epigastrium most marked $1\frac{1}{2}$ inches above the navel in the midline. There is some soreness in the lower right quadrant of the abdomen. Nervous, slight tremor, reflexes normal. Basal metabolic rate plus 70 per cent. Both superior poles have been ligated and as a result the basal metabolic rate has dropped to plus 1 per cent.

Preliminary ligation is always done if the basal metabolic rate is over plus 50 per cent. or if the patients appear very ill, even if the rate is lower than 50 per cent. If the basal metabolic rate is over a plus 75 per cent. or the patient seriously ill, we never do a double ligation. If the rate is over 100 per cent. we do not even do a single ligation. It has been our experience that in those patients with a basal metabolic rate of over 100 per cent. that, if they are put in bed and given absolute rest, given sedative sufficient to keep them quiet, an ice-collar about the neck, no visiting except for a few moments each day with one or two of the closest relatives, they will improve and the basal metabolic rate drops to 100 per cent. or below. Since Plummer's report on the use of Lugol's solution in these cases we have been using it, although our results have not been very different than they were before.

The patients for ligation are sent to the hospital a day or two or more before the operation, according to the patient's condition. Sleep the night before is assured by the use of sed-

atives Two hours before the operation morphin, $\frac{1}{8}$ grain and scopolamin, $\frac{1}{16}$ or $\frac{1}{32}$ grain, is given hypodermically One hour before the operation we give morphin, $\frac{1}{8}$ grain, and atropin, $\frac{1}{16}$ grain, hypodermically For the local anesthetic we give $\frac{1}{2}$ of 1 per cent novocain with no adrenalin, as the use of adrenalin occasionally results in a fatality For the preparation of the skin we are using picric acid 5 per cent in 95 per cent alcohol instead of iodin

There are a few points I want you to especially notice about the operation First, the incision Care must be made in making the incision, for many patients, especially women, judge the result of the operation as much by the appearance of the scar as they do by the alleviation of the symptoms Formerly it was the custom to wear ribbons about the neck, and incisions made over the isthmus could be covered by a ribbon But women no longer wear ribbons about the neck Beads and necklaces, however, never go out of style, so that an incision made where a string of beads would normally lie can easily be covered This is important because, while most of the scars become faint after a year or two, at first they appear red, and in a case of those people who have a tendency to overproduction of scar tissue the scar will always appear prominent The second important factor in making the incision is to have it symmetric, and the third, to hold the knife perpendicular to the skin because when the skin is cut on a level the scar is much more apt to be thickened than when at right angles with the surface of the skin The incision is made through the skin down to but not into the platysma The upper flap is then reflected above the prominence of the larynx and the lower flap about $\frac{1}{2}$ inch We have tried many ways of retracting the skin, but have found that the Farr retractors work better than any other method (Fig. 436) One pair is placed on each side.

The second point that I want to call your attention to is the care of the muscles. Formerly we cut the ribbon muscles, but during the past two years we have been retracting them to the side, and find we can deliver even the largest goiters by this method, for in the patients with large goiters the muscles have

already been stretched to where they have become thin bands, and hence easily displaced laterally. While this may seem a trivial matter, it is of considerable importance to the comfort of the patient following operation. The muscles are first separated longitudinally in the midline. With our fingers we free the fascia from the surface of the thyroid and insert a Farr retractor (Fig. 437). It spreads the muscles sufficiently to deliver an ordinary goiter, one lobe at a time. In larger goiters a

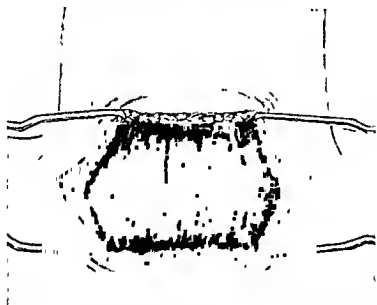


Fig. 436—A low collar incision has been made through the skin and subcutaneous fat down to the platysma. The upper flap has been freed to a point above the prominence of the larynx and the lower flap to a distance of about $\frac{1}{2}$ inch. Farr retractors have been inserted on either side.

small retractor may be inserted on one side by an assistant and the muscle pulled farther over, or the retractor may be fastened by a strip of gauze and a clothespin to the rack holding the sheet over the neck between the anesthetist and the field.

The third point is the protection of the parathyroid bodies. I want you to notice the method of delivering the thyroid gland. We never put our finger or instrument back of the thyroid gland because of the danger of injury to the parathyroid bodies. A Japanese physician, whose name I have forgotten, working a

few years ago in the Children's Clinic and the Pathologic Institute at the University of Vienna, was able to show in the post-mortems upon children who had presented either active or late symptoms of tetany that there had been previous hemorrhage into the parathyroid bodies which had probably taken place at birth. We never know how many normal parathyroid bodies a given patient may have, thus, it is possible by putting our fingers and instruments behind the thyroid gland to traumatize the parathyroid bodies that are functioning in the cases in which



Fig 437—The muscles have been split in the midline and the thyroid gland freed by passing the finger between the thyroid and the muscle. A Farr retractor separates the muscle, exposing the thyroid.

some of them have been destroyed, and tetany develop as the result. Instead of lifting the lobe from behind we grasp it with tenaculum forceps (Fig 438) and lift it upward, care being taken not to use traction enough to disturb the trachea or other structures that are lying close to the thyroid. Another precaution that we take to protect the parathyroid is to preserve the blood-supply. The arteries of the parathyroid are branches of the inferior thyroid arteries, so for that reason we do not ligate the inferior thyroids, but instead ligate their branches within the gland.

Fourth, ligation of the upper pole. Sometimes severe bleeding which it is difficult to stop comes from the retraction of the superior thyroid artery or its branches after they are cut, making it difficult to grasp them. Before we make any incision in the gland we pass a pair of forceps from the midline out under the upper border of the thyroid gland. It must be carefully passed

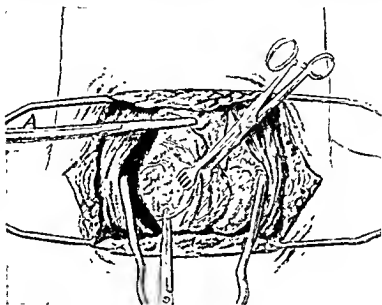


Fig 438.—A forceps passed from within outward posterior to the thyroid gland. The posterior blade of the forceps, *A*, was seized with the anterior blade passing anterior to the lobe, drawn posterior to the upper pole. The forceps was then closed, crushing the tip of the upper pole. The right lobe of the pole has been seized by tenaculum forceps and lifted forward and to the left, so that the vessels on the surface of the thyroid may be seized along the margin of the posterior capsule. After the removal of the greater portion of the lobe an over-and-over suture is taken around forceps, *A*, through the remaining portion of the upper pole. The forceps is then withdrawn and the suture tied similar to the method used on the broad ligament in salpingectomy.

so as not to include any other structures. The forceps is then opened and we grasp the lower blade of another forceps whose upper blade is so opened that it will pass anterior to the lobe. The lower blade is then drawn through posterior to the pole and the second forceps clamped (Fig. 438, *A*). After the removal of the greater portion of the lobe an over-and-over suture is

taken about the forceps, the forceps is removed, and the suture tied.

Fifth, the amount of gland to remove. There has been much discussion in the literature in times past as to how much of a thyroid gland should be removed. It has been our rule to leave the posterior capsule and a small amount of adherent gland. In the exophthalmic type of goiter it is possible to leave too much gland, but so long as the posterior capsule is allowed to remain intact, it would be rather difficult to remove too much, because with a thin slice of thyroid gland left adherent to the capsule there will be enough regeneration to take care of the needs of the patient. In other types of goiter it has been necessary to leave a little more of the gland. Before making the incision through the capsule we grasp the vessels along the surface of the capsule and then with a sharp knife cut through the gland, leaving a thin slice adherent to the posterior capsule.

Sixth, protection of the recurrent laryngeal nerve. The most important step in the protection of the recurrent laryngeal nerve is not to expose it because in so doing it may be injured. The branches of the inferior thyroid artery within the gland are caught with curved hemostats held perpendicular to the long axis of the body. The purpose for holding the hemostats in this manner is to protect the recurrent laryngeal nerve, there being more danger of injuring it if we grasp vessels crosswise to its long axis. The nerve runs along a groove between the trachea and esophagus, and if the posterior capsule of the gland is left intact and a hemostat placed as described above, there is very little danger of injuring the nerve. Occasionally there will be an inflammatory induration following operation which may produce a temporary injury. This cannot always be prevented, but a complete recovery usually follows this complication.

Seventh, hemostasis. Complete hemostasis must be secured. The arteries and bleeding veins should be caught with artery forceps and ligated. For this we use No. 1 plain catgut because we have found that chromic gut will often keep up a serous exudate for some time after operation. This exudate sometimes continues until the piece of irritating catgut is dis-

charged through the sinus. Such a sinus is very apt to be followed by an increase in amount of scar tissue and tugging of the skin as well as widening the scar at the point at which the sinus occurred.

Eighth, drainage. An unpleasant complication, especially with women, is the tugging of the skin of the neck upon swallowing. This is due to connective tissue extending from the trachea to the skin, usually along the course of the drainage-tube. To avoid this we have been draining at the angles of the wound external to the sternomastoid muscle. The sternomastoid is picked up and an artery forceps passed back of its external border to the thyroid gland and then a small rubber tube drawn through.

Ninth, closure of the wound. After complete hemostasis the retractor holding the muscle is removed, allowing the muscles to fall together in the midline. They are then sutured with a continuous No. 1 plain catgut suture. The retractors are then removed from the skin and three interrupted subcutaneous catgut sutures are placed. The skin is then closed with skin clips, great care being used to see that the margins of the skin come in exact apposition, the drains being brought out at the extreme external angles.

Tenth, the dressing (Fig. 439). It appears to be but a little point, but we have found that an easy fitting non-irritating dressing adds much to the postoperative comfort of the patient. Next to the wound we place a small piece of gauze soaked with alcohol. This is covered with two long dressings, and over this we place an ordinary surgical pad cut to fit the neck. This is held in place with tapes attached to adhesive strips. Two of the strips are placed posterior to the shoulder in such manner that the tapes will be at the upper corners of the dressing. The other two strips are placed over the breasts external to the nipples, extending to the side of the chest in such manner that the tapes are at the lower angles of the dressing. The tape from one shoulder is then tied to the tape from the opposite breast and then the other pair tied in the same manner. The dressing, as you see, is held firmly yet comfortably in place. The simple untying of the strings permits of the changing of the dressing

without any discomfort to the patient, such as occurs where extensive bandaging or adhesive is used. The adhesive tapes are not removed as long as the wound requires dressing.

Eleventh, after-care. After the patient has been returned to bed an ice-collar is placed about the neck, morphin, $\frac{1}{2}$ grain, with atropin, $\frac{1}{150}$ grain, is given if necessary to control pain or rest-

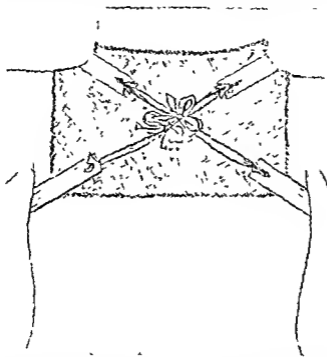


Fig 419 —An ordinary surgical pad has been cut to fit the neck and adhesive strips with tapes placed back of the shoulder and over the breast to the lower surface of the chest. The tapes are tied across the dressing. The dressing is held firmly in place and yet can easily be removed for inspection of the wound.

lessness. If the heart action becomes rapid, 10 mm. of digilin is given intramuscularly. Digilin should always be given intramuscularly, as when given subcutaneously it causes considerable discomfort with many patients. The patients are put flat in bed and allowed to be propped up as soon as they desire. The drains are removed usually at the end of twenty-four hours and the

skin clips on the third day. Should there be an accumulation of fluid after this, it is aspirated, or should there be too much for aspiration, a very small opening is made with the aspirating needle through the wound. Frequently when there is an accumulation of fluid we have hot moist applications put on the neck. In a large number of cases this will result in the sufficient opening for the drainage to escape, and yet an opening not large enough to result in an increase in the size of the scar. The patients usually leave the hospital within a week.

In conclusion, gentlemen, I wish to emphasize the importance of a careful study of each patient as an individual. The condition of the gland and the resistance of the patient must be carefully estimated, as toxic patients are highly nervous and must be treated with the utmost care. Details of but little importance in other fields of surgery must be given the greatest consideration in the treatment of toxic goiter. When the highly toxic goiter patients are treated as ordinary surgical cases the mortality is high, but with a careful consideration of all the details connected with each individual patient, there is no disease treated by the surgeon that gives such satisfactory results. The mortality should be not greater than a fraction of 1 per cent.

CLINIC OF DR. EVERETT O. JONES

SWEDISH HOSPITAL, SEATTLE, WASHINGTON

PERSISTENT THYROGLOSSAL DUCT

WE have this morning 2 cases illustrating a congenital anomaly, associated with the development of the thyroglossal duct. The condition of persistent thyroglossal duct cannot be called a common occurrence, yet one cannot speak of it as being altogether rare. It occurs sufficiently often to be frequently mistaken for abscesses about hair-follicles, branchial cysts, tuberculous sinuses, and the like, unless one remembers the dogmatic teaching that all midline cervical cysts and fistulæ are to be considered as coming from the thyroglossal duct until proved otherwise.

Case I.—Mrs. H. J., married, forty-five years of age, first consulted me about a month ago for a persistent sinus in the lower part of the neck. She stated that when twenty-two years of age she first noticed a lump in the midline of the neck. It grew slowly and was quite painless. Five years later she was operated on and a cyst removed. A discharging sinus developed quite promptly thereafter. Since then she has submitted to five additional operations, all of which were unsuccessful.

In the midline of the neck at the level of the cricoid cartilage there is an irregular, red, adherent scar, with a center of red granulation tissue. In this is a pinhead-sized opening which, on pressure from above, exudes a drop of thick, yellowish fluid. The sinus admits a fine probe for about $\frac{1}{4}$ inch. The history which she gave is quite typical of these cases as we usually first see them, the frequent unsuccessful operations being due to the surgeon not recognizing the true nature of the condition and therefore not excising the whole tract.

This is essentially a developmental anomaly. As you know, the thyroid gland makes its appearance in embryonic life at the base of the tongue and later migrates down through the structures of the neck until it reaches its normal adult position. When the tract which it leaves in its migration later fails to atrophy and become obliterated, as it normally should do, it forms a duct lined with epithelium, the same epithelium as lines the pharynx. This epithelium possesses the power of re-



Fig 440—Radiograph of thyroglossal duct injected with sodium bromid solution

generation to a marked degree and so after an incomplete removal we see a very prompt reappearance of a sinus.

When this lady was being examined it occurred to us that it would be a very valuable thing to demonstrate the exact extent and location of the sinus. We know how successfully sodium bromid is used in pycelography and so thought that, if we could inject the tract with a sodium bromid solution, we should be able to demonstrate it by means of a radiograph. By using a needle which filled the orifice of the sinus snugly we succeeded

in injecting about 1 c.c. of a 20 per cent. sodium bromid solution and obtained this radiograph (Fig. 440). You see that the duct is outlined quite clearly. You notice that it is quite intimately associated with the hyoid bone and that it extends well up to the base of the tongue.

This is quite important in formulating a method for its complete removal, as we shall see in a few moments. I have been unable to discover thus far in the literature the report of a successful radiographing of a persistent thyroglossal duct. Several writers mention unsuccessful attempts with silver solutions and

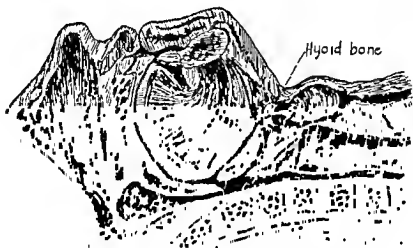


Fig. 441 —Schematic drawing of thyroglossal duct and cyst

bismuth suspensions, probably because the injected fluid was too thick to penetrate the fine lumen of the duct

The field of operation having been prepared, we will proceed with the first step, which is the injection of the anesthetic solution. We always prefer to do these operations under local anesthesia for several reasons. In the first place, the neck is a most favorable location for the successful use of local anesthesia. When well applied the anesthesia lasts long enough so that the operation can proceed without hurry. Plenty of time can be taken for a careful dissection. There is no anesthetist in the way and, what is of the greatest importance, the use of local anesthesia absolutely precludes all rough handling and pulling

of tissues, and forces the surgeon to acquire a gentle touch and to use a careful, sharp-knife dissection throughout the operation.

We use $\frac{1}{2}$ per cent. novocain solution, with the addition of 5 drops of adrenalin to each ounce. With a very fine needle six intradermal wheals are made at the following points. At the posterior margin of the sternomastoid muscle, on a level with the angle of the jaw, and on a level with the upper edge of the thyroid cartilage on each side of the neck. That makes four. The two other points are in the midline of the neck, one just

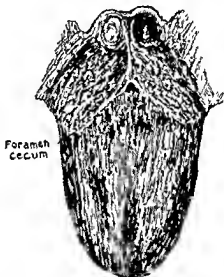


Fig. 412.—Dorsum of tongue showing foramen cecum.

beneath the jaw and the other over the thyroid cartilage. A long, moderately large needle is then introduced into the first wheal, back of the angle of the jaw, and pushed in until it comes in contact with the tip of the transverse process of the third cervical vertebra. Ten c.c. of the solution are then injected. At the two wheals on the line of the thyroid cartilage the needle is pushed in until the point pierces the cervical fascia, when 10 c.c. more are injected on each side. At the point over the thyroid the needle is introduced down to the cartilage and then deflected laterally along each upper edge, 10 c.c. being injected on each

side. At the point under the chin the needle is introduced under the fascia, and then carried along under the bone, depositing solution as it is advanced clear out to the angle of the jaw on each side. Finally, the subcutaneous tissues connecting the six points are infiltrated with the solution. This forms an irregular, four-sided figure, within which the entire operation is conducted (Fig. 443). From 10 to 12 ounces of the solution are used.

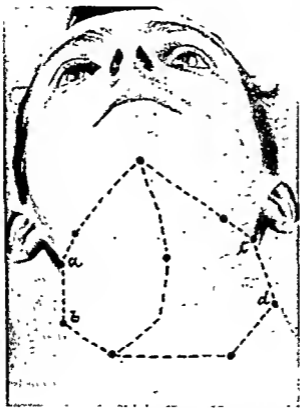


Fig. 443 —Diagram showing points for injecting local anesthetic.

We will now wait fifteen minutes for the anesthetic to take effect. This is a very important thing to remember. Many a carefully applied local anesthesia has been spoiled by undue haste on the part of the surgeon to begin the operation. If the first incision through the skin is attended with any pain, the patient's morale is so upset that, even though subsequent steps of the operation are quite painless, she exaggerates every sensation of pressure or traction into the most exquisite agony,

whereas, if the first cut is **painless**, her confidence is established and the operation can be carried out with very little discomfort.

We have seen from the radiograph that the tract is very fine and that it is intimately associated with the body of the hyoid bone. We do not know whether it passes behind the bone or directly through it. Anatomic studies of the thyroglossal duct have shown that it may take either course. Therefore, it has been found that to attempt to isolate the duct and dissect it out always invites failure. The only safe course is to core out a strand of tissue sufficiently large to be handled easily and to include with it the center of the hyoid bone.



Fig. 441 —Drawing showing tract dissected out.

So far as I have been able to find, this radical procedure was first recommended by Eliot, of New York, in 1908. Spencer, of London, in 1914 reported the resection of the hyoid bone for the cure of thyroglossal fistula. But the generality of surgeons did not recognize the importance of this procedure, until in the last few years papers emanating from the Mayo Clinic have popularized the method.

We have found that this dissection is greatly facilitated by injecting the tract with a staining fluid, and for this purpose we

use a 1:1000 aqueous solution of gentian-violet. This is used on the recommendation of Doctor Nickson, the hospital pathologist, who tells us that gentian-violet has a greater power of penetrating living tissue than any other aniline dye. With a needle which fits snugly into the sinus we inject 2 c.c. of the stain. You notice that the patient is splitting purple-stained saliva, a very graphic proof of the extent of the tract.

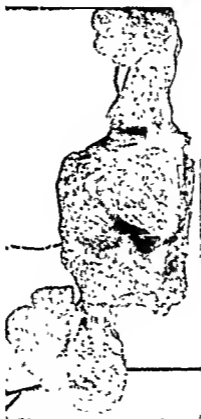


Fig 445 —Photograph of tract after removal.

The anesthesia is now complete and we will proceed with the dissection. Two transverse incisions are made, encircling the old scar. All the cicatricial tissue is dissected up. The skin and platysma are reflected up and down. There you see the purple-stained tract, a little over $\frac{1}{8}$ inch in diameter, lying between the vertical muscles of the neck. We know this tract contains the duct. Following the line of the stain we dissect the tract free

up to the hyoid bone. The muscle attachments are separated from the body of the hyoid with a periosteal elevator and the center of the bone removed with cutting pliers. Following the line of our stain, the strand of tissue is cored out between the deep muscles under the chin. Now we have exposed the mucous membrane at the base of the tongue. The duct is crushed with a clamp close up under the mucous membrane, ligated, and divided.

In carrying out the dissection above the hyoid bone we must bear in mind the relation to it of the foramen cecum. It lies in the midline upward and 45 degrees backward from the upper edge of the body of the hyoid. With a single catgut suture the cut edges of the hyoid are brought together. You see all the muscles are accurately approximated and the cavity we made is entirely obliterated. A small rubber drain is placed up to the hyoid. This will be removed in twenty-four hours. The skin is closed with a subcuticular stitch. You will have noticed that the patient has made no complaint throughout the operation.

Case II.—Our second case, Miss McK., twenty-eight years of age, a stenographer, first consulted me a few days ago. She stated that when a small child she had a fluctuating swelling in the midline of the neck which was thought to be an abscess and was lanced. A discharging sinus remained. A year ago she underwent an operation to cure this fistula, which was unsuccessful.

Examination of the neck disclosed a ragged and irregular scar at the level of the thyroid cartilage. In the center of the scar is a pinhead-sized opening, from which a drop of clear mucus can be expressed. In this case we succeeded in getting an even clearer radiograph than we did in the first case, showing the tract running up through the hyoid bone to the base of the tongue.

We will carry out the same operative procedure we did before, using local anesthesia, and injecting the tract with the gentian-violet. The scar here is not so unsightly as in the first case, so one transverse incision through the skin, passing around the opening of the sinus, will be sufficient. We now have the

entire tract dissected out and will clamp it high up and remove it. You see one suture is sufficient to bring all the structures accurately together in the midline. We will make the same skin closure here as in the other case. We ought to get a better cosmetic result in this case because there is very little cicatricial tissue in the skin.

In order to understand the pathology of the thyroglossal duct one must be familiar with those parts of the embryo which enter into its formation. In the human embryo the tongue arises, not as an organ of the mouth, but develops as a median elevation on the ventral wall of the pharynx and later grows forward

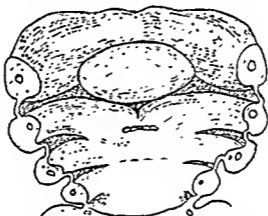

Fig. 446 — Drawing of schematic embryo, showing development of tuberculum impar.

into the buccal cavity (Fig. 446). This projection, the tuberculum impar, forms eventually the anterior two-thirds of the tongue. The posterior third arises from two lateral prominences which come from the ventral ends of the second branchial arch. These posterior lobes are first separated from the anterior portion by a V-shaped groove. From the apex of this V a pouch-like depression develops and later thickens into a lobed mass of cells, which elongates to form a stalked vesicle, connected with the dorsum of the tongue at a point which persists into adult life as the foramen cecum (Fig. 447).

The thyroid gland, thus formed in its development, descends in the tissues of the neck and takes its adult position on the ven-

tral surface of the trachea. By the time this migration is completed the stalk of the vesicle has normally become obliterated and disappears. In the normal human embryo this process is complete by the fifth week of the fetal life. About this time the mesoblastic cells of the segment, which is later to form the hyoid bone, begin to develop and cartilage cells make their appearance. In a certain proportion of cases (Mayo states that it is as high as 40 per cent) there is a delay in the descent of the thyroid, so that it becomes entangled in the mesoblastic cells which are developing in the hyoid bone.

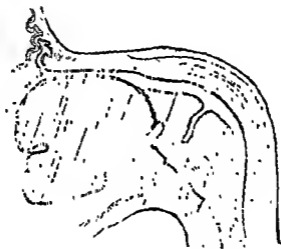

Fig. 447 — Longitudinal section of embryo, showing descent of thyroid

From this circumstance arise certain developmental anomalies. These consist either in the failure of the descent of all or portions of the thyroid, giving rise to the so-called accessory thyroids, or to the failure of the stalk to obliterate, causing the persistent thyroglossal duct, or the canal of His. It is readily seen, therefore, why a complicated course exists, if the stalk of the thyroid bud fails to obliterate either in whole or in part. The tract would pass from the foramen cecum on the posterior part of the tongue caudally and somewhat ventrally to the mid-line of the neck, through the body of the hyoid bone, then along

the ventral surface of the upper part of the trachea to the isthmus of the thyroid. This course explains the difficulty which is usually encountered in the surgical removal of lesions developing in this structure.

The persistent thyroglossal duct is lined by one or more layers of epithelium which are generally ciliated, unless these structures have been destroyed by repeated infections. In the walls of the duct occur numerous mucous glands of a simple type. Their secretion gives rise to the discharging fistulæ which so often make this condition of special interest.

Another phenomenon is the persistence of islands of thyroid tissue along the course of the duct. These may occur at any point from the foramen cecum downward. They are prone to occur where the thyroid gland in its normal position is incompletely developed. While persistence of the entire tract occurs, much commoner are lesions involving isolated portions of the tract. Furthermore, observation has shown that there exist certain points of election, at which the majority of these lesions occur.

It has been seen that in the descent of the thyroid duct its stalk comes into intimate association with the mesoblastic structure, forming the hyoid bone. The hyoid then forms a point of division. Lesions developing from the portion of the tract, extending from the foramen cecum to the hyoid, constitute the suprahoid group, while those coming from the portion below the bone form the infrahyoid group. Figure 448 (after Cbemin) shows the sites of election, three associated with the suprahoid portion and two with the infrahyoid.

There are three classes of lesions associated with the thyroglossal tract: (1) solid tumors; (2) thyroid rests, and (3) cysts. Cysts are the lesions which most commonly result from a persistence of a whole or a portion of the duct. Often, when the patient is first seen by the surgeon, he presents a sinus, but this has always been preceded by a cyst which has either ruptured spontaneously or has been opened under a mistaken diagnosis. The essential structure of these cysts is quite constant.

When no inflammatory changes have taken place the walls

are thin and transparent and consist of consecutive layers of connective tissue lined with epithelium, which is columnar and often ciliated. There are numerous glands which secrete a viscid, faintly turbid fluid. Where inflammatory changes have taken place the walls are thickened, the glands distorted, the epithelial lining modified or destroyed, and the contents changed to thick, turbid mucus or pus. Cysts frequently become infected "spontaneously", that is, by the hematogenous route or by extension from the mucosa of the nasopharynx.

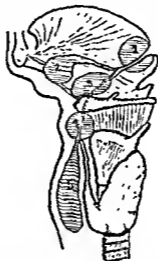

Fig. 448 — Diagram showing possible sites of aberrant thyroid (after Chenu)

Thyroglossal cysts are always in the midline, anywhere from the base of the tongue to the level of the thyroid, differing in this respect from lesions resulting from persistent branchial clefts which are always lateral. Their time of appearance also distinguishes these lesions. Branchial fistulae are always present at birth, while thyroglossal cysts always appear later and may not develop until adult life.

When a thyroglossal cyst ruptures spontaneously or is opened by a physician a discharging fistula always remains. The sinus is always in or very near the midline of the neck and may be at any level, depending on the distance downward to which the

cyst has extended. These lesions are to be distinguished from branchial fistulæ, on the one hand, and from sebaceous cysts, abscesses, and broken down tuberculous glands, on the other. If one keeps in mind the location and the time and manner of development, the differential diagnosis should not be difficult.

The persistent thyroglossal duct, as it is encountered clinically, consists of the frankly cystic or patent portion and then, attached to its upper extremity, is a fine, thread-like structure which looks like a fibrous cord, which usually penetrates the center of the hyoid bone, and loses itself in the muscles of the base of the tongue. Unfortunately this structure, which looks like a fibrous cord, usually contains a minute lumen, the lining of which is capable of regeneration. The permanent cure of this condition, therefore, demands the complete dissection of the cyst or fistula, together with all the tissues along the central portion of the hyoid bone. Nothing less can assure permanent cure. Since we have adopted this method of treatment we have had no recurrences.

THE USE OF INTRAVENOUS INJECTIONS OF GLUCOSE AND INSULIN IN CERTAIN POSTOPERATIVE EMERGENCIES

I WISH this morning to call your attention to the use of glucose and insulin in certain postoperative emergencies, to relate our experiences in the past few months, and to suggest that quite possibly we have here a valuable addition to our surgical armamentarium.

It is my purpose simply to describe our clinical experiences and to suggest some deductions from the clinical evidence.

Attention was first called to this subject by an article of Thalheimers appearing in the Journal of the American Medical Association.

He described 3 cases attended with serious postoperative complications, each differing somewhat in its clinical phenomena, but all having the common underlying condition of acidosis, and concludes that the brilliant results following the treatment were due to the combating of this condition.

We owe our success with the treatment wholly to Dr. Nickson, the hospital pathologist. From the first he has taken great interest in the subject and has been very enthusiastic over it. I am going to ask Dr. Nickson to describe the preparation of the solution and its method of administration

DR. NICKSON: The glucose solution is made from water and 5 per cent. of either dry or syrup glucose. This is then put in a sterilizer and held at 15 pounds' pressure for twenty minutes. This stock solution is capped and held ready for use at any time.

The intravenous apparatus employed is that commonly used for giving salt solution. The only consideration being not to run the solution into the vein too fast. The only way to avoid this is to use a needle having a caliber No. 22 or No. 20. ⁴ The glucose solution, when to be used, is heated from 40° to 45° C. and 1 unit of insulin is added for every 2 grams of sugar in this solution. The solution is then well shaken and poured into the

with an acute appendicitis. She was immediately operated and a perforated appendix removed. The belly was filled with a thin, milky, odorless pus. There was no evidence of adhesions anywhere.

The following day her condition was very critical: a thin rapid pulse, cyanosed lips, and the skin covered with a cold perspiration; the abdomen was distended and she was regurgitating small quantities of brown liquid. Her stomach was washed out, and 1000 c.c. of glucose and 1 c.c. insulin given intravenously. The response was just as prompt and satisfactory as in the first case. The improved condition lasted about eight hours, when a relapse set in. The treatment was repeated and improvement again followed. This continued for seven days, when the little patient died.

A postmortem disclosed that death was due to general peritonitis, pus being present in every portion of the abdominal cavity.

Throughout her illness the urine was scanty, highly acid, and contained acetone.

The third case was a woman thirty-eight years of age who had a streptococcus blood-stream infection following a pelvic infection.

Her illness was abrupt in onset, marked by daily chills and very high temperature, lasted four weeks, and ended fatally. Intravenous injections of glucose and insulin were given repeatedly without having any effect on the course of the disease; not even a temporary amelioration of the symptoms. It may be said in passing that this was equally true of the intravenous injection of mercurochrome acriflavine gentian violet.

The fourth case, a machinist, thirty-six years of age, was struck in the back by a falling timber, July 1st, which produced a compression fracture of the bodies of three dorsal vertebrae. A month later, because of constant pain and disability, it was decided to do an Albee bone-transplant operation. This was done August 5th. The operation lasted about an hour and the patient left the table in apparent good condition. Four hours later he was in a condition of extreme collapse. He was pulseless, the lips were blanched, the skin bathed in cold sweat, and

he was only partially conscious. He was immediately given glucose and insulin. This had but very little effect. The pulse would pick up a little, only to flag again. The pallor and sweating was unmodified.

Blood transfusion was then resorted to, 500 c.c. taken from his brother being given. The patient responded promptly to this treatment and the following day he was in good condition. At no time did this patient's urine show the presence of acetone or any increased acidity.

The fifth case, an old gentleman seventy-four years of age, who has had a large scrotal hernia for fifty years, most of the time being irreducible. He was compelled to submit to an operation because of recurring attacks of partial intestinal obstruction. The operation (August 11, 1924) was done mostly under local anesthesia, with the addition of a small amount of gas. The patient left the table in excellent condition. The following morning his temperature was normal, pulse 77, abdomen soft, but he was vomiting small amounts of dark fluid and hiccuping constantly. His stomach was washed out and he was given glucose and insulin, with improvement, which lasted throughout the day. The next day he was again as bad or a little worse than on the previous day. The treatment was repeated, with improvement, followed by relapse. The patient became unconscious, hiccuping and vomiting almost constantly, the vomitus frequently consisting of pure blood. All this time the temperature was normal, the pulse of good quality, never above 80, the skin dry and warm. Intravenous injections were persisted in until all the available veins were used up, when hypodermoclysis was resorted to, giving 100 c.c. each hour.

The patient continued in this state for twelve days, when he rather abruptly regained consciousness and stopped hiccuping and vomiting, and went on to a slow, but, on the whole, satisfactory convalescence. Throughout the illness the urine was scanty, the low point being 8 ounces in twenty-four hours. Acetone was always present in large amounts and occasionally a trace of sugar was found. In all, 32,000 c.c. of glucose solution were given, with 1 c.c. of insulin to each 1000 c.c. of the glucose.

The sixth case, a barber, thirty-six years of age, was operated September 1st for cicatricial ulcer of the pylorus, a pylorotomy being done. The patient left the table in excellent condition. The following morning his temperature was normal, pulse 90, abdomen soft, he was vomiting dark colored fluids and hiccuping. The urine gave a strong reaction to acetone. He was immediately given 2000 c.c. of glucose with insulin, and this was repeated in six hours. His vomiting and hiccuping stopped at once and he had no further trouble.

Now to recapitulate briefly our observations.

The first case I looked upon as an acute toxemia. In the process of opening a walled-off appendical abscess the system absorbed a single overwhelming dose of toxin which depressed carbohydrate metabolism to the point where ketones were allowed to be formed in large quantities. The time elapsing between the operation and the onset of the serious symptoms, about eighteen hours, would be sufficient for the development of such an acidosis.

A somewhat similar condition was present in the case of the little girl, only here a rapidly developing infection in the form of an acute peritonitis was present. Temporary improvement was noted after each injection, only to be followed by relapse as additional quantities of toxin were taken up by the system.

The fundamental nature or cause of the different types of ketosis is not known, but physiologists agree that either because of an absence of carbohydrates or because of a depression of carbohydrate metabolism the body fats and proteins are split up and incompletely oxidized, giving rise to ketones as by-products. Whatever the original cause, a vicious circle is soon established, the persistent vomiting giving rise to a starvation acidosis which tends to perpetuate the condition until the circle is broken by throwing a quantity of glucose with insulin into the circulation. This furnishes the necessary metabolized carbohydrates to oxidize the ketones and so eliminate the acidosis.

The two last cases described furnish entirely different clinical phenomena, and yet the condition of acidosis seems to be the underlying causative factor.

CLINIC OF DR. A. E. ROCKEY

GOOD SAMARITAN HOSPITAL, PORTLAND, OREGON

APPENDICITIS

APPENDICITIS in fact, or fancy, we have always with us. It is in our first thought properly associated with pain in the lower right quadrant of the abdomen. It must be remembered that serious, even gangrenous, appendicitis may occur without pain. If acute, this may mean anything from an acute suppurative appendicitis to an attack of renal colic. If chronic, it may mean enterolithiasis in the appendix, stone in the ureter, and a variety of pathologic conditions about the cecum, or a neurosis without demonstrable pathology. If we would avoid the pitfalls of useless operation, or of overlooking or neglecting what may prove serious, we must be cautious and thorough in our diagnosis

We have this morning an opportunity of presenting for operation 2 cases of acute appendicitis. They represent different types. They promise well as instructive illustrations. The recent occurrence of several other operated cases, which are still in the hospital, will give us an occasion for a ward walk to present types of cases, and note what has followed during the convalescence. What is of great importance in this connection is to notice those requiring drainage, and those in which it has not been used. Fortunately this morning we can demonstrate different methods, complications, and results.

Of the 2 cases one began in the night, and came into the hospital only two hours ago. The other has been ill for several days, and is probably ruptured, and contains free pus. The proper operative sequence is to select the one which offers the least danger of spreading infection in our operating-rooms, that

might endanger the less infective case, or rather the one probably less infective.

Case I.—The patient we select first is Robert B, fourteen years of age, a pupil in a military school. He was engaged in play as usual, felt a bit ill about dinner time last evening, ate only a little dinner, concluded that he had eaten something which disagreed with him, vomited shortly after his dinner, then went to bed, and to sleep as usual. He awoke at 6 o'clock this morning, with fever and some general abdominal discomfort. The matron at the school telephoned the hospital, and after a preliminary examination by the school physician he was sent to the hospital for examination and diagnosis as an appendicitis suspect. On further inquiring into the case, we find this lad has been generally well, and actively engaged with his fellows in work or play. He has never had a previous attack. Except for measles, he has had none of the ordinary infective diseases of childhood. He has not had influenza. The bowels have been regular, and no cathartic has been administered. He complains now of some discomfort in the lower right quadrant of his abdomen. He prefers to lie on his right side with his limbs flexed.

On examination his temperature was found to be 101° F. The leukocyte count was 14,000, with 86 per cent polymorphonuclears. In making an abdominal examination in acute appendicitis, the first thing to observe is the attitude of the patient in bed, and the movements and contour of the abdomen. On inspection of the abdomen when he is turned on his back we find the abdominal movements comparatively normal, with a little tendency to fixity of the lower abdomen in respiration. In palpating the acute case we always begin on the left side. This is to accustom the patient to the touch of the hand, and the examiner also senses the general tension of the abdomen. Proceeding gradually upward on the left side, and across the abdomen, he proceeds downward toward the right lower quadrant. In this instance a definite difference in the tension of the muscles on the right and left side is immediately discernible. When the pressure is increased in the vicinity of McBurney's point, a

definite rigidity, or rather spasm, of the rectus muscle is induced, and the patient complains of local tenderness. Palpation of the loin evinces no definite tenderness. This point should not be overlooked, as tenderness there means one of two things, either an extremely posterior location of an acutely inflamed appendix, or it is also notable in kidney involvement. Our diagnosis is acute appendicitis unruptured. When the case has progressed to the point of rupture, the pain increases gradually until that happens, and then the patient regards himself as markedly better. That is an ominous state of affairs, for the reason that many patients are regarded as having made definite improvement at the time that takes place, and there is then no increase in pain until the inflammatory condition has spread beyond the immediate locality of the perforation.

Gas-oxygen-ether sequence of anesthesia being now complete to the point of relaxation, we will proceed to operate by transverse incision. You will find this incision described in the *Annals of Surgery* of May, 1924. We have been using it continually and continuously with occasional exceptions for twenty years, and regard it the simplest, easiest, and most efficient operation for definitely diagnosed acute appendicitis that is offered in surgical literature. In the case before us the abdomen is comparatively free from fat. It is the muscular abdomen of a youth, and will enable you to observe the various essential points in the surgical anatomy of the operation. The cutaneous incision is made directly across McBurney's point. It begins over the middle of the rectus muscle, and is extended through the skin and subcutaneous tissues to the fascia overlying the muscles from the middle of the rectus outward, just above the anterior superior spine. This will probably cross just above the level of the base of the appendix. The principal point of tenderness was just below this line and a little to the outer side. We next incise the fascia over the sheath of the rectus, and extend it outward through the aponeuroses of the abdominal muscles. There are no muscle-fibers cut. As soon as the rectus is exposed, it is drawn inward with a retractor into the sheath, and the incision is deepened through the aponeurotic

junction of the abdominal muscles until the peritoneum is exposed, and carried outward through the aponeuroses until the beginning of the muscular fasciculæ is evidently in the outer end of the incision. At this point, unless the operator is overfastidious about using the handle of the scapel for this purpose, it may be used below, and the finger above, pushing down slightly the

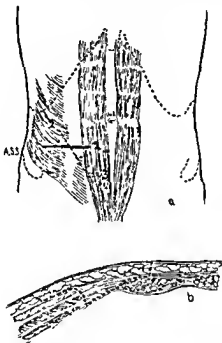


Fig 449 —a, Surgical anatomy showing relation of the author's incision to those of McBurney and Wier. b, The tissues incised before making the exposure of the peritoneum, by spreading the incision and introducing retractors, are shown above the dotted line. (Redrawn from *Annals of Surgery*, May, 1924.)

surface of the peritoneum to spread the incision by a vertical pull parallel to the edge of the rectus. This pull should spread the incision wide apart. It is a very important feature of technic in the operation. A narrow retractor (the one we use has a blade about $\frac{3}{4}$ inch wide) is now introduced into the outer angle of the incision, and the one at the inner end pushes down on the

surface of the peritoneum, and draws the rectus muscle more snugly toward the inner side. We now pick up the peritoneum, nick it with a knife, slip in a probe-pointed scissors, and extend the incision in the peritoneum on the same transverse line inward and outward the full length of the external incision. A little slightly turbid fluid appears, which indicates at once

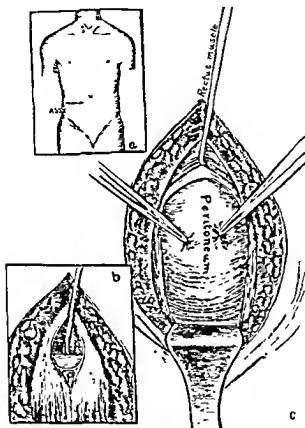
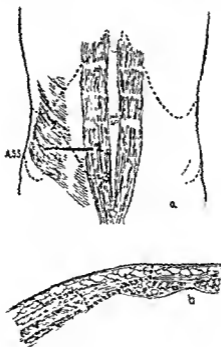


Fig 450—*a*, Surface location of the incision. *b*, The key at the outer border of the rectus *c*, The peritoneal exposure. (Redrawn from *Annals of Surgery*, May, 1924)

that we are in the close locality of the inflammatory action. The index-finger of the right hand is now introduced into the abdominal cavity, and slipped carefully downward, keeping close to the anterior abdominal wall. We at once feel a definite sense of local hardness, which is probably the inflamed appendix. Swinging it first outward, that is, toward the right iliac fossa,

junction of the abdominal muscles until the peritoneum is exposed, and carried outward through the aponeuroses until the beginning of the muscular fasciculæ is evidently in the outer end of the incision. At this point, unless the operator is overfastidious about using the handle of the scapel for this purpose, it may be used below, and the finger above, pushing down slightly the



May, 1924)

surface of the peritoneum to spread the incision by a vertical pull parallel to the edge of the rectus. This pull should spread the incision wide apart. It is a very important feature of technic in the operation. A narrow retractor (the one we use has a blade about $\frac{3}{4}$ inch wide) is now introduced into the outer angle of the incision, and the one at the inner end pushes down on the

omentum, which peels off as the appendix comes upward into the incision. As we bring it out of the abdominal cavity the base of the appendix is directly in the incision line. We have not seen small intestine, and we carefully exclude it, and mop up the slightly turbid fluid with a moist gauze sponge. For the purpose of demonstrating the condition better to you we will catch the meso-appendix rather close to its base with a pair of curved hemostats, and raise it directly into the incision. The assistant will hold it where you can all observe it, and we will clamp the meso-appendix closer to the cecum with another clamp, and insert a No 2 plain catgut ligature close to the cecum just beyond the tip of this clamp. The turns for a tie are made, and the clamp is slipped off, and the catgut firmly tied in the groove that it has left in the meso-appendix. This secures the circulation, and the meso-appendix is now cut off down to the base. The appendix itself is now crushed with a narrow straight-bladed hemostat. Another pair of forceps is clamped across the appendix just distal to this. A purse-string of No. 00 chromic catgut is passed with a plain round No. 5 darning needle in $\frac{1}{4}$ -inch bites in a circle about $\frac{3}{4}$ inch in diameter around the base of the appendix. The proximal forceps is removed, and a ligature of plain catgut tied in the groove. The appendix is now cut off between the forceps and the ligature and the end wiped with carbolic and alcohol. The ligated end is pushed in, and the purse-string drawn up and tied. We will inspect carefully the results of the procedure this far, drop the cecum, and draw forward the omentum over the operative site. A case of this sort requires no drainage. The peritoneum is closed with continuous No. 2 catgut suture. The transverse incision is now approximated by two No 2 chromic sutures, passing through the aponeuroses and fascia at the edge of the rectus sheath. They are placed about a centimeter apart, and must include all of the fascial and aponeurotic structures. These are what we call the key sutures because they close that part of the abdomen on which there is likely to be any tension. We use chromic gut for them to hold them securely until union takes place. A few chromic No. 2 stitches in the separated muscular

edges and a few in the sheath of the rectus completes this part of the operation. The skin is approximated with interrupted silkworm sutures.

Case II.—Our next patient is a woman fifty-five years of age, and presents a somewhat different history. She has been ill for a week. At the beginning of her abdominal discomfort she took several doses of salts. Free catharsis resulted, but it was followed by increasing pain and soreness, which was treated by hot applications. A physician was called, who made a diagnosis of appendicitis, and advised her removal to the hospital. As often happens, the patient declined to accept such a diagnosis, and continued treatment herself. She was seen by her physician again yesterday, who insisted that his diagnosis was correct, and that a surgeon should be called. They consented to this, and I saw her late yesterday evening at her home. The patient and the family stated that she was much better. She had had no pain since morning. On examination her temperature was 102° F., and there was distinctly palpable a sense of hardness in the lower right quadrant. The diagnosis of acute appendicitis was confirmed, with the additional observation that the appendix had ruptured, and that its vicinity was now the site of an abscess. Under the circumstances it was felt to be entirely advisable to send the patient to the hospital, and wait over until this morning for operation. She was re-examined just before the beginning of our clinic this morning. Her temperature was 99.5° F. The leukocyte count was 22,000, with 86 per cent. polymorphonuclears. The sense of resistance on palpation is even a little more definite than it was when she was sent to the hospital. We may expect in this case to find a ruptured appendix, with extravasation of fluid and walled-in pus. There is no class of cases in which the value of the transverse incision is better illustrated than in the one before us. The operation will be done within the adherent region, and any further opening of the peritoneal cavity, if required, will be done without any extensive invasion of uninfected portions.

Now that the patient is anesthetized to the point of relax-

ation, the difference between the local resistance of the induration, and the spasm of rigidity from muscular tension, is readily demonstrated. Where the rigidity is from the latter cause it disappears with anesthesia. Where it is due to induration, extravasation, or localized abscess, it may lose some of its tension, but remains palpable. The incision is made on the lines before described. The abdomen is rather fat, and the external incision is for that reason longer. The fascia has now been uncovered, and is incised exactly as before described. Again let me invite your attention to those very essential points of technic, the opening of the fascia of the rectus, the drawing inward the outer border of the muscle, the separation of the aponeuroses to the peritoneum, the up-and-down pull to open wide the incision, and the insertion of retractors at the inner and outer ends, drawing the rectus firmly into the sheath, and spreading the split inner ends of the three broad abdominal muscles wide apart in the same line. We have used broad retractors here, and you will see now what a surprisingly large area of peritoneum has been readily uncovered. We now palpate the peritoneum to feel through it more definitely the area of induration underneath. The abscess is just below the line of incision at the outer part. We bear this in mind as we open the peritoneum. We come at once to adherent omentum. This is carefully separated, chiefly to the lower and outer border of the abdomen. We may expect to reach the abscess from this point. Free fluid is now coming out of the wound. It is not the creamy, yellowish pus that is found in more advanced cases, but is of a slightly reddish character. Progressing downward a little further, we enter what seems to be a more definite abscess. The pus is more yellow. A little further at the inner side we encounter an indurated mass, which undoubtedly contains the appendix. It does not turn out readily, as in the previous case, but with your mind's eye, the end of your finger being careful to do no violence, you work along the lines of least resistance, and succeed now in loosening a mass, which we will gradually work into the incision. In this we find the appendix, and a mass of adherent omentum. Several courses will be open to us. One would be to insert a

edges and a few in the sheath of the rectus completes this part of the operation. The skin is approximated with interrupted silkworm sutures.

Case II.—Our next patient is a woman fifty-five years of age, and presents a somewhat different history. She has been ill for a week. At the beginning of her abdominal discomfort she took several doses of salts. Free catharsis resulted, but it was followed by increasing pain and soreness, which was treated by hot applications. A physician was called, who made a diagnosis of appendicitis, and advised her removal to the hospital. As often happens, the patient declined to accept such a diagnosis, and continued treatment herself. She was seen by her physician again yesterday, who insisted that his diagnosis was correct, and that a surgeon should be called. They consented to this, and I saw her late yesterday evening at her home. The patient and the family stated that she was much better. She had had no pain since morning. On examination her temperature was 102° F, and there was distinctly palpable a sense of hardness in the lower right quadrant. The diagnosis of acute appendicitis was confirmed, with the additional observation that the appendix had ruptured, and that its vicinity was now the site of an abscess. Under the circumstances it was felt to be entirely advisable to send the patient to the hospital, and wait over until this morning for operation. She was re-examined just before the beginning of our clinic this morning. Her temperature was 99.5° F. The leukocyte count was 22,000, with 86 per cent. polymorphonuclears. The sense of resistance on palpation is even a little more definite than it was when she was sent to the hospital. We may expect in this case to find a ruptured appendix, with extravasation of fluid and walled-in pus. There is no class of cases in which the value of the transverse incision is better illustrated than in the one before us. The operation will be done within the adherent region, and any further opening of the peritoneal cavity, if required, will be done without any extensive invasion of uninfected portions.

Now that the patient is anesthetized to the point of relax-

makes it more desirable to remove it than to leave it in place. The meso-appendix is thick and indurated, and we ligate it with plain No. 2 catgut. No effort is made in such a case as this to bury the appendical stump. We ligate it close to the base with chromic No. 2 catgut ligature, cut it off, and avoid any further manipulation. This case we will drain with a rubber drain

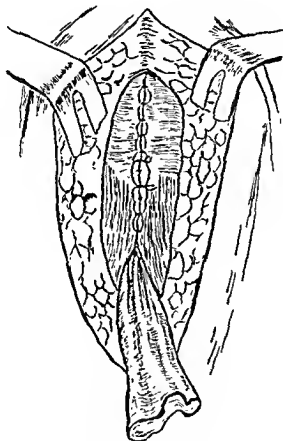


Fig. 453.—Key sutures tied. Fascia closed (redrawn from *Annals of Surgery*, May, 1924).

cut from a glove wrist. The sutures are placed as in the previous case, except that the folded glove wrist comes out through the split muscles external to the key sutures. The case resembles somewhat the one which our illustrator used in making the sketches for the articles referred to, which we have had enlarged and placed on the board. Figure 452 shows the drain in position.

and the remaining figures illustrate the steps in the operation as I have described it.

In addition to the transverse incision such a case as this should have a dependent drainage. When the ordinary right rectus incision is made in suppurative appendicitis, and the patient is placed in bed in a semisitting position, the entire basin of the pelvis is still below the incision line. Drainage must then take place, first, by the fact that the opening of the abscess has offered that as a point of least resistance, and, second, when a cigarette drain is introduced it acts by capillarity for a short time until the meshes of the gauze become clogged with pus corpuscles and fibrin. Following that the drain still acts as a point of least resistance, because the cohesion of living tissues to the surface of the gutta-percha tissue is less than adhesions of the intestinal coils, which quickly takes place. Notwithstanding these favorable factors drainage is still a difficult pull. We place the patient in a lateral position, in which the outer end of the incision is at the lower end of two inclined planes, the one from the pelvic plane down to the level of the iliac crest, and the other down from the diaphragm to the same point. After the patient is put to bed I shall ask you to go with me to the room to see that the direction of this position has been fully carried out. The patient is tilted a little forward of a directly lateral position. The upper portion of the trunk is raised on two pillows. At this time the right thigh is flexed, and the left more extended. Bodily comfort is much greater than in a semi-upright position. The position of the limbs may be varied, the right extended and the left drawn up as you see in Fig. 455, and yet the outer and inner incision is the lower point of the abdomen. We may expect this patient to recover without incident. The rubber dram by virtue of the dependent position is efficient from the first, and, as a rule, continues so.

These adjustments having been made, we now go to the children's ward to see a case recently operated on, which by reason of the complications of neglect has had an extremely stormy convalescence, but is now on the high road to recovery. This lad is twelve years of age. He had been ill for three days

before coming to the hospital, having generalized abdominal pain, localizing in the right lower quadrant with vomiting and fever. The day before coming here he was seen by his physician, who advised immediate operation. The family did not want this done, so they gave him a dose of castor oil, and got some appendicitis medicine from a drug store. He became very much worse. His pain, which had been localized in the right lower quadrant, became general over his abdomen, and he vomited several times, which he had not done since the first day.



Fig. 454.



Fig 455

Figs 454, 455 —The lateral position for dependent drainage, showing variations for comfort (redrawn from *Annals of Surgery*, May, 1924)

Operation through a transverse incision disclosed a gangrenous appendix, necrotic in its entire length, lying outside and behind the cecum. There was a diffuse peritonitis with no limiting adhesions, with foul pus. The appendix was removed, and two cigarette drains placed from the appendical site, and brought out at the outer angle of the incision. Patient put to bed in the usual position on his right side. He made a fairly smooth convalescence for two days, and then began to vomit. His vomiting became regurgitant in character, with typical upper intestinal

tive. Urine negative. It was now decided that this was an inflammatory intra-abdominal process, either appendicitis with an abnormally placed appendix, or Meckel's diverticulitis.

Operation performed through a median incision between the symphysis and the umbilicus. The pathology found was extensive adhesions, some apparently recent, some apparently old and dense, between omentum, bladder, loops of intestine, and the appendix, which ran across the pelvis. About 2 drams of thick pus was evacuated. A concretion about the size and shape of an olive stone was removed, with a little necrotic tissue. This concretion was white in color, hard as hard putty, and quite smooth on the surface. It was considered better judgment to drain, and not to perform the burdensome operation that would have been necessary to remove the appendix. Accordingly this was done, two small cigarette drains being placed in the pelvis, and brought out through the lower angle of the wound, which was then closed in layers.

The child was put to bed with the head of the bed elevated, and carefully cared for. The postoperative course has been satisfactory. It is now eleven days since the operation. The child is making a satisfactory recovery. It may never have another attack of appendicitis, or it may have.

The so-called attacks of biliousness, which the child has had for many months, were evidently mild attacks of appendicitis, which relieved themselves by permitting the accumulating secretion to discharge back into the lumen of the bowel through the proximal part of the appendix. This is a condition which may very well represent a true chronic appendicitis. Just how long these cases last as such, and when they promote an acute fulminating attack, it is difficult to say. The soft concretions may occur at any age, and may be long in causing definite trouble. I have seen a few concretions containing mineral substances enough to give a distinct click to the knife. I remember one in a man fifty years of age, who gave a long history of what was evidently a chronic appendical irritation. He was operated during an acute attack. The appendix had perforated, and a considerable sized abscess had formed. He

had been ill for several weeks when the abscess cavity itself evidently ruptured, and there were still further extensions. He was operated through a transverse incision with dependent drainage, made a good recovery, and was immediately entirely cured of the chronic symptoms he had had so long.

I want to invite your attention to the position in bed which we have chosen for this child. She is sitting up in bed in what is practically a Fowler position. In this case the appendix being pelvic, probably retrovesicle, the lateral position would not be suitable.

When appendicitis occurs in children with definite localized pathology it is more frequently than anything else due to concretions in the appendix. There are some in which there is general gangrene of the appendix, and some with localized inflammatory conditions of the mucosa, but real appendicitis in children means pathology. The extent of the inflammation may be such that it is inadvisable to do anything more than opening and putting in a drain. These cases often recover, but subsequently require operation. A year or more ago we operated on a nine-year-old boy, who had been operated on three times before. His condition was always so serious when he came to operation that previous to this time it had been deemed inexpedient to search for the appendix. In passing let me say that this often represents good surgical judgment. It is better to have a live child who is liable to recurrence of appendicitis, than it is to have the pathologic specimen and the death certificate to be signed. On the occasion to which I refer we found and removed a pelvic appendix by a vertical incision just at the inner border of the right rectus muscle. The appendix lay retrovesicle. The patient made a good recovery.

As we leave the children's ward I want to give you the history of a recently operated case that has gone home well. Master T., aged fourteen years, had always been well. Three days before entering the hospital he had abdominal pain, supposed to have been due to eating chicken salad. He had some vomiting and diarrhea. Pain localized in the right lower quadrant, and remained there. He had temperature.

Examination showed abdomen soft, except in right lower quadrant, where a tender mass could be felt. Diagnosis. Perforated appendicitis with localized peritonitis.

Transverse incision was made. Peritoneum opened, with escape of thin pus. Appendix lay extracecal, and bound down in its middle portion. It had perforated at a spot about its middle, and possibly a concretion had come out at this point. We were unable to find it in the abscess. The appendix was removed and stump buried. One cigarette drain was placed at the stump and brought out at outer angle.

The patient made a smooth, uneventful convalescence.

We will now go to one of the men's wards to see Mr. H. On the way from the children's ward let us seek a sequestered place in the end of the hall, while I make you a few remarks on the uncertainties of diagnosis in acute appendicitis. This is suggested by the various diagnoses that have been made in the case we have just seen, and also by the fact that only a few days ago a case came to my mind when I met one of our prominent pediatricians in the hall of the hospital, and reminded him of the case, which for the time being had escaped his memory. I was called by him late one evening to operate on a case of acute appendicitis in a little boy four years of age. He had a temperature of 103° F. There had been some vomiting during the afternoon, and there was a distinctly palpable mass definitely tender in the lower right quadrant. I examined the case myself, and confirmed his diagnosis. The symptoms apparently were too plain to be misunderstood. What closer picture of appendicitis could one wish to see? Fever, vomiting, and a mass that seemed as large as a hen's egg, or nearly that, on palpation. Why trouble to go further? I do not recall such details as blood-count, etc., at this time, as I am speaking from memory. What we found, however, I shall never forget. Opening the peritoneum it was found perfectly normal, and the mass was found to be retroperitoneal. Opening a little wider, and looking in, it was found to be the right pole of a horseshoe kidney. The appendix was entirely normal, and was not disturbed. The incision was closed, and the child made an uneventful recovery.

What it had was some infective gastric upset, which is not uncommon in children, and which with the singular coincidence of the horseshoe kidney was easily mistaken. This is only another illustration of the care required in making a diagnosis.

The first patient which we will now see in this ward illustrates the dangerous use of morphin. Two days before coming to the hospital he had generalized abdominal pain. A physician was called to relieve his pain, which he did by administering a hypodermic injection of morphin, which gave comfort until the next day, when pain recurred. At this time it had definitely localized in the right lower quadrant. The abdomen was soft, except in this region, where there was marked tenderness and rigidity. Fortunately the physician who had given the morphin in the night was absent the next morning, and another one was called, who diagnosed an acute appendicitis, and sent him into the hospital. There was certainly more good luck than surgical judgment in this man's escape from a second dose of morphin, which he probably would have had.

It is scarcely necessary to remind you, although this gives us an opportunity to emphasize it, the danger of two very common procedures in acute abdominal cases. One is the administration of cathartics, and the second is the giving of morphin to relieve pain. I would like to suggest that on the case of every hypodermic syringe manufactured be engraved "Do not give morphin until you have made your diagnosis." Morphin has its definite use for the relief of pain, but it should never be given before the diagnosis is made. Many a perforated duodenal ulcer, perforated appendix, or perforated gall-bladder has been lured to death by the comfort of a hypodermic injection. Many a case of intestinal obstruction, or of localized sepsis, has gone beyond by the pernicious agitations of active cathartics.

Mr. H. is fifty-one years of age. His general health has always been good. The history of his present illness I have just related to you.

We found his temperature to be 101° F., leukocyte count 22,000, and polymorphonuclears 85 per cent.

He was operated on through transverse appendical incision.

There was a small amount of free fluid. The appendix was gangrenous. The tip was large, bulbous, and fluctuant, the outer covering seeming almost as thin as tissue paper. During the removal this was ruptured, spilling a small amount of pus. The appendix was removed retrograde. There was no omentum in the right lower quadrant. It was not seen during the course of the operation. One cigarette drain placed at the site of the appendix, and brought out at the outer angle of the wound.

The patient was put to bed and turned on his right side. He has made a very smooth convalescence. His drain has been removed, his wound is almost healed, and he is up on a back-rest part of the day.

We have in this ward Sergeant C, who is up and around, and will be able to go home in a few days. He is twenty-nine years of age. About ten days before admission to the hospital he had an attack of supposed food poisoning, from which he was thought to have recovered. The day previous to operation he had abdominal pain, more on the right side, and nausea without vomiting, temperature 102° F.

Examination showed the abdomen not involuntarily rigid, but voluntary rigidity and spasm easily elicited. Tenderness from epigastrium down entire right side, and around right flank, but greatest 1 inch inside and above the anterior superior spine.

Transverse incision was made. When the peritoneum was opened there was a small amount of clear free fluid. Palpation revealed a mass lying behind the intestine in the right lumbar gutter. Evidently there was terminal ileum densely adherent to the right posterior lateral abdominal wall. The incision was extended outward and upward, and the line of cleavage was found, the intestine freed from the abdominal wall, and a mass of necrotic tissue excised. Part of this necrotic tissue was omentum, and part evidently the appendix, but it was so markedly changed by gangrene that no distinct structure was apparent. Two cigarette drains were inserted to the place from which the necrotic appendix was removed.

He was put to bed, turned on his right side, and made a very smooth convalescence.

To summarize my remarks this morning, we may say first of all that appendicitis is a pathologic condition, which may be at times acute, and fulminating, depending on infection with microbes of great virulence, or may be chronic with a definite mechanical basis in the way of retained concretion, which produce necrosis by pressure, sharp kinks which permit an occasional filling, and discharge of retained concretions, gangrene from thrombosis, either associated with mechanical factors or due to infections of unknown origin. Right-sided pains, which may be mistaken for real appendicitis, may be of neurotic origin, and have no basic pathology in the appendix itself. Operation in the former class of cases is imperative sometimes, and advisable always. Operation in the latter class of cases is inadvisable, and only seldom leads to recovery. A large proportion of the neurotic cases, or those with other troubles, have recurrence, or continuance of their symptoms, and bring no credit to the diagnostician and operator, and no advantage to the patient.

Prophylactic appendectomy should be done in many cases when the abdomen is open for other causes. This is particularly true in those which involve the gall-bladder, stomach, or duodenum. Prophylactic appendectomy is, of course, always done through the same incision which was made for the purpose of the operation.

True acute, fulminating appendicitis, the condition chiefly under consideration this morning, is one in which the incision should reach the site of operation most directly with the least anatomic disturbance of structures. It should be sufficiently ample for a complete operation, and to deal with the necessary complicating pathologic conditions as acute and old adhesions, the extension of inflammatory action, and proper dependent drainage in those cases which require drainage. These requirements are more satisfactorily provided than by any operative method in surgery through the transverse incision which we have described, and by dependent drainage in the lateral position, with the patient turned on the right side, the shoulders and upper part of the chest slightly raised. This is the position which perhaps the majority of people assume in normal sleep.

CLINIC OF DR. OTIS FLOYD LAMSON

SWEDISH HOSPITAL, SEATTLE, WASHINGTON

ADHESIONS OF THE UPPER ABDOMEN

THIS operative case we have this morning is one of unusual interest because the patient apparently has received no relief of the subjective symptoms for which I operated previously. She is now giving me another opportunity. It is not my desire only to help her, but I wish to find whether or not, and how, my surgery has been at fault. The cases from which we learn really valuable lessons are those which develop postoperative complications, or after a temporary recovery return with the same or worse symptoms.

The chief complaint of this patient prior to the first operation was nausea and vomiting, with aching and distress over epigastrium and extreme weakness.

The patient had an attack of influenza in March, 1924, when she was confined to bed for six days. She has not been well and strong since. Ten weeks ago she began to have digestive difficulty. Food became distasteful to her. It did not "taste or smell right" and nauseated her.

There was a feeling of general distress, but not definite pain. Sometimes she felt a "knocking and pounding" of the heart. This had no special relation to her meals and would come on at any time. She also complained of marked salivation, expectorating small amounts of clear mucid substance accompanied with a feeling of something "like a ball" rising to her throat.

She has never been jaundiced

She had been confined to bed for three weeks prior to the first operation, as she felt too weak to be about, due to her inability to retain food. She has lost 15 pounds in weight since the influenza attack.

Physical examination showed rigidity over the epigastrium with marked tenderness. No masses were palpable. There was no visible peristalsis.

Stomach contents showed no free acid, total acidity 11.5, and no occult blood.

Blood-sugar, 142 mg per 100 c c

The roentgenologic examination was unsatisfactory. There seemed to be very active peristalsis, the food passing through very rapidly. A second examination had to be discontinued due to lack of co-operation on the part of the patient.

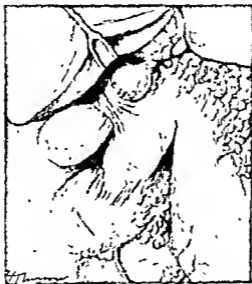

Fig. 456—Adhesions of the upper abdomen

The gastric symptoms seemed out of proportion to her objective evidence of abdominal disease, so it was decided to have a careful neurologic examination made to rule out any disease of the central nervous system as a cause for vomiting. This was done, including spinal puncture, Wassermann test, blood and spinal fluid—all were negative.

This lady was operated four weeks ago for symptoms stated in the history given. Preoperative diagnosis then was cholecystitis. When the abdomen was opened the diagnosis was

verified, besides the gall-bladder was found adherent to the duodenum as far as the midportion of it, and so constricted as to make it a characteristic hour-glass gall-bladder (Fig. 456). In all, there seemed to be sufficient cause for the digestive disturbance and the pernicious vomiting of which she particularly complained. I therefore performed a cholecystectomy.

On further exploration of the abdomen, the appendix was found moderately inflamed and the base bound against the cecum by a mass of adhesions. The appendix was removed. Other organs seemed normal. The patient made a very prompt recovery from the operation and began taking nourishment at the end of forty-eight hours and experienced no vomiting until the end of the second week, when she again became nauseated and had occasional vomiting. This condition gradually became worse until finally she could hardly take even water. The vomiting continued so persistently and perniciously that she became very weak and her pulse mounted to as high as 160. It was apparent that she had a definite mechanical obstruction that necessitated surgical interference.

Therefore she was again submitted to the routine preoperative examination. Attempt was made to give her a barium meal for x-ray examination, but she retained very little of it. However, the following morning the x-ray showed that there was still some barium left in the stomach. The pernicious vomiting and the presence of barium still in the stomach made us feel that we were dealing with a case of postoperative obstruction of the duodenum probably due to adhesions. It is surprising how often and how well with the aid of x-ray one may diagnose pathologic conditions of the stomach and intestinal tract. The clysmas of barium meal rarely fails to locate the position of adhesive bands and show the degree of the consequential ptosis of the bowels.

To prepare her for this operation yesterday she was given subcutaneously 2000 c.c. of normal saline morning and evening in order to increase the body fluids. This has improved her condition considerably. The pulse has come down to between 130 and 140 and she seems now a little stronger.

We are using ethylene anesthetic. We have great confidence in it, as we have found that in very serious cases such as this, when a short anesthetic with complete relaxation is desired, that it gives better service. We have had no untoward effects from it. There follows less nausea and vomiting than after ether. The patient goes to sleep very much more quickly than with either gas or ether. Frequently I have been able to make the incision less than three minutes after the beginning of the anesthetic.

We are making a midline incision in this case in order to avoid the adhesions which we would necessarily encounter by going through the incision made in the previous operation. Of course, first of all, I explore the site of my first operation—cholecystectomy. On examination, I see that the duodenum is drawn up and fastened to the gall-bladder fossa by dense adhesions—dull, glistening, white fibrous bands—too dense to be called a membrane, highly vascularized, with many small blood-vessels—rising and spreading out from the point of origin of the adhesions (Fig. 457). Also there are similar adhesions extending from the duodenum to the parietal peritoneum, causing partial ptosis of the duodenum. Such adhesions are generally so closely attached to the peritoneal coat of the bowel that it is almost impossible to separate the agglutination without deperitonizing and leaving a raw and bleeding surface ready to adhere to any tissue that may come in contact. It is well to differentiate such adhesive bands from membranes—which are thin and transparent, spreading veil-like over the bowels like Jackson's membrane that spreads over the cecum, and is so attached to the covering of the bowels that it can be resected without injury to the peritoneum or the gut wall. But a resection of such adhesive bands as we see here is almost impossible and often unwise.

On account of the patient's extreme weakness we will not make an attempt to loosen the adhesions and perhaps injure the duodenum. We may successfully relieve the obstruction by doing so, but the chances are that they would recur in a greater mass than at present. Therefore, and also to avoid any un-

necessary manipulation and trauma to the bowels, I will leave the adhesions as they are and will perform a posterior gastro-enterostomy. This, I feel, is the safer method to pursue in this case.

The problem that presented itself in the first operation was how to promote normal healing, yet prevent the formation of

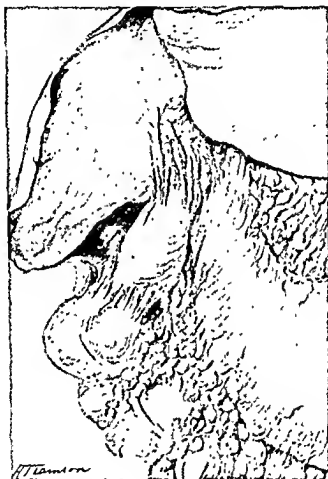


Fig. 457.—Adhesions of the upper abdomen

harmful adhesions, especially when operating on the upper abdominal quadrant where organs most frequently involved are located—such as the gall-bladder, the duodenum, and the transverse colon.

Now a different task is before us, and the ultimate result de-

depends on judgment rather than on technic. It is my opinion that when great masses of dense vascular adhesions are present and cannot be released without deperitonizing the gut wall and paving the way for further difficulties through larger masses of adhesions, to leave them alone and side track the structures involved—by doing an anastomosis, such as we have done in this case. This may be done in other regions of the alimentary canal. I have had occasion to perform an iliosigmoidostomy on account of obstruction to the colon, particularly the transverse




Fig 458 —Adhesions of the upper abdomen.

colon, due to massive adhesions, with gratifying results (Fig. 458).

In certain cases, also, I can see where it might be advisable to do an anastomosis between loops of the small intestines where there is a likelihood of recurrence. Naturally this method of treatment of adhesions applies to only selective cases. It goes without saying that the operation which changes the normal anatomy the least and at the same time promises good results should be the operation of choice

Before we close the abdomen it is well to see that we have a clean field—with no blood-clots, no exposed raw surfaces—thus the primary causes of postoperative difficulties have been guarded against.

On account of the weakened condition of the patient, it is very necessary that as little time as possible be consumed in doing this operation—which is now completed and the abdomen is closed. The anesthetist informs me that the patient's condition is fully as good as it was before the operation. There has been no increase or decrease in the blood-pressure and the pulse has come down and is in better condition. I therefore feel that we have done the operation which has subjected the patient to the least amount of risk, still giving her all possible chances for complete recovery.

Postoperative difficulties due to adhesions is a condition which follows a great many major abdominal operations, therefore it is to us of paramount importance, yet its etiology is frequently misinterpreted. Often the formation of peritoneal adhesions is a part of healing, and while they should be properly guarded by the surgeon, not necessarily always prevented. Most of us think of adhesions as troublesome aftermaths of operation and cherish a horror against them. This is not surprising, as our attention is only then drawn to them when they are interfering with the function of a vital organ, often undoing a great surgical effort, leaving the patient in a more hazardous condition than before the operation. The lay-patient knows enough of surgery to hold the surgeon more or less responsible for any such postoperative functional disturbance. They too are unaware of the fact that there are beneficial or harmless adhesions, and as nature's efforts of healing they are valuable.

For convenience, we may divide postoperative adhesions into two classes: First, those which we may call harmless, that is, although they may be quite numerous, they are so located that they do not interfere with the function of the structure involved. Second, harmful adhesions which seriously hamper the work of some organ, as in this case, or extend between loops of the intestines, constricting them in such a way as to cause complete

obstruction, demanding immediate surgical relief, these may be referred to as massive and harmful adhesions (Fig 458). These may be divided into two general groups:

- (1) Preoperative
- (2) Postoperative.

Preoperative adhesions may be caused by inflammatory processes, such as cholecystitis, appendicitis, pelvic inflammations, small perforations of the stomach or bowel, or by trauma from external violence, or large tumors injuring neighboring structures

Postoperative adhesions may be caused by infections, use of drains; or trauma from rough handling of the viscera, through the use of too hot sponges, not protecting sufficiently denuded surfaces or by failure to check bleeding

It seems to me that the most important means of preventing adhesions is the employment of prophylaxis. First, it is imperative that we operate in such a way as to cause as little trauma to the organs as possible. It has been reported that too hot sponges have been the cause of postoperative adhesions. It is important to operate as rapidly as can be done safely, and exposing the peritoneum and viscera to as little air as possible. Therefore the Trendelenburg position as in pelvic operations is advisable. It allows the intestines to gravitate away from the field of operation. The use of the reverse Trendelenburg position in stomach and gall-bladder cases serves the same purpose.

Second, it is very important to peritonealize as much as possible all denuded surfaces with viable grafts of peritoneum, and where it is impossible to do this it is best to make use of omentum or fat, thus promoting agglutination and vascularization.

Literature abounds with suggestions of various foreign materials—non-absorbable membranes such as Cargile membrane—to protect the surfaces until regeneration of the endothelium has taken place. Even various lubricants, such as vaselin, liquid petroleum, gum-acacia, gelatin mixtures, have been used to cover the denuded areas, but thus far their usage has not been justified.

Third, the extensive use of drains should be avoided. By this I do not mean we should fail to use one when definitely indicated. It is quite likely that the use of drains following a cholecystectomy has a tendency to produce more adhesions between the duodenum and the gall-bladder fossa than the removal of the gall-bladder without drain. Personally I prefer to use a drain on account of the fact that following the absorption of the catgut sutures used in ligating the cystic duct there is apt to be an escape of bile for a few days. It seems to me that the presence of the bile without a channel to bring it to the surface would promote the formation of adhesions more than the presence of a drain.

It is well to bear in mind the peculiar fact that some patients have a tendency to form adhesions even when the trauma to the organs has been very slight. Very extensive adhesions have been found after apparently minor operations. If we had any way of determining which patients have such a tendency, it would be, no doubt, better to allow them to suffer from the disease they have rather than give them something worse.

CHRONIC PERFORATING DUODENAL ULCER WITH TUMOR FORMATION

THIS patient, sixty-two years old, a stockman by trade, has been having trouble with his stomach for fifteen years. His chief complaint is a gnawing pain with sour eructation three or four hours following inception of food. He would often awake at night with acute pain, and find relief only by taking some solid food or soda. He states that these attacks were first intermittent. He would be comfortable for two or three weeks, then pain would set in and last four or five weeks. It would be worse in the spring and fall. The attacks became more aggravated and more frequent during the past two years, and finally he sought surgical relief. On February 2, 1924 a posterior gastro-enterostomy was done.

The report from the doctor who operated is as follows: "Patient had chronic ulcers of stomach and duodenum." "Upper jejunum had appearance of tuberculosis." "Section was removed and sent to pathologist, whose diagnosis of tissues was inflammatory, not tuberculous."

Patient was better for four months following the operation, and his former symptoms—gnawing epigastric pain, sour eructations and vomiting—returned. He then came to me.

I find the patient undernourished, but of ruddy complexion.

On the abdomen there is a scar in the upper right rectus and tenderness in the epigastrium. No masses or organs are palpable.

Radial pulse shows marked arteriosclerosis.

Test-meal:

Free HC—0.

Total acidity—70.

No lactic acid.

Positive for blood.

x-Ray taken on July 30, 1924 showed both six-hour and twenty-four-hour residue. Only very little barium had gone

through the gastro-enterostomy opening. On August 18, 1924 none appeared passing through the pylorus.

Though the patient has had a recent posterior gastro-enterostomy, he has now almost complete pyloric obstruction. His condition is worse than before the operation. Our x-ray plates indicate a large gastrojejunal ulcer completely obstructing the new opening.

I am making my incision in the midline a little to the left of the former incision. We feel a mass in the duodenum extending from the pylorus down nearly as far as the common duct. On account of the location and the long history of symptoms of duodenal ulcer I feel that we are dealing here with chronic perforating duodenal ulcer with the resulting inflammatory mass. I do not consider that the mass is malignant.

In spite of the history given me by the patient, I find that no gastro-enterostomy has been done. This puts a new light on the case. We are dealing here with the primary condition. The operation done five months ago evidently consisted only in the removal of glands which later proved to be only inflammatory. I cannot conceive what could have prompted the surgeon to deceive the patient in the operation he had performed.

Strange as it may seem, the x-ray picture which we have here before us indicates a partially obstructed gastrojejunal opening (Fig 459). However, in view of his weakened condition, we will not attempt to remove the mass which we consider to be inflammatory, but we will perform a posterior gastro-enterostomy which I feel will give him complete relief. If I did find the necessity to do a pylorotomy, it would be done in a two-stage operation. The patient's present condition warrants only a gastro-enterostomy now and later the removal of the tumor.

The gastro-enterostomy is now completed. Apparently the patient has suffered very little shock. The anesthetist reports that his condition is excellent.

I regret to say that this patient has not had a square deal. He has been deceived and his life has thereby been in jeopardy. While I do not believe that extreme neurotic patients should be told of every phase of the operation and its probable complica-

tions, yet it is their solemn right to know what is done to them when they are under the influence of anesthetics.

Posterior gastro-enterostomy still holds a very important place in surgery of the stomach, and it is very doubtful if any form of pyloroplasty can show as good results in the treatment of most cases of duodenal ulcer, particularly when the ulcer has partially obstructed the duodenum.



Fig. 459.—Chronic perforating duodenal ulcer with tumor formation.

With the history of a former gastro-enterostomy, together with the x-ray findings, I felt we were dealing with a gastro-jejunal ulcer with obstruction at the site of the new opening.

Had this been a marginal ulcer, as we anticipated, it was our intention to take off the gastro-enterostomy and do some type of pyloroplasty. Marginal ulcer usually calls for a pyloroplasty after taking off the gastro-enterostomy. We may excise the ulcer satisfactorily, but we cannot be sure that there will not be

a recurrence This is so frequent that we are not justified in doing a simple excision without disconnecting the gastro-enterostomy The fact that gastrojejunal ulcer occurs in only about 2 per cent of gastro-enterostomies justifies the operation from a percentage standpoint

The few cases that go wrong following gastro-enterostomy are particularly applicable for pyloroplasty. It has been advanced in favor of plastic operations on the stomach and duodenum that we are not changing the anatomy so much as in gastro-enterostomy. But we cannot get away from the fact that we are destroying the pyloric ring with its sphincteric action which is nearly as much of a change as the making of a new opening into the stomach as in gastro-enterostomy. Then, again, the neutralizing effect of the alkaline secretions from the gastrojejunal opening is no doubt a factor in the prevention of ulcers re-forming

I sometimes think in our mad search for new methods we are too apt to cast aside old and tried operations which have given a very high percentage of good results. These experiments too often result in failures and thereby work a great hardship on the patient and do not help the advancement of surgery.

**MULTIPLE ABSCESSSES OF THE LIVER TREATED INTRA-
VENOUSLY WITH MERCUROCHROME—COMPLETE
RECOVERY**

THE patient that we wish to study today is, as you see, a Japanese, thirty-five years of age. He has now been in the hospital nearly five months. This patient was referred to us by Dr. B. M. Tanaka. In order to save time, we will give just a few of the salient features.

He came into the hospital on January 10th. He had been sick for nearly a week before entering. On January 14th, he was operated upon for appendical abscess. The appendix was removed and the stump ligated with chromic catgut; three cigarette drains were used. About 6 ounces of thick, foul pus was evacuated. His convalescence was without incident until six days after his operation. At this time, January 20th, he had a severe chill and his temperature arose to 103° F. This was repeated the next day. He had no chill the 22d. Had chills the 23d, 24th, 25th, and 26th, with temperature from 102.5° to 105°. His leukocyte count was uniformly high at this time—22,000, with an 86 per cent poly. count. Wassermann was negative. Urine examinations were negative. The possibility of multiple abscesses of the liver was considered.

For a few days his temperature was not high, and then from February 1st to 28th he had daily chills and temperature, varying from 102° to 105° F. Frequently the temperature would be normal or subnormal a part of the day. There was very little change in the respiration, and the pulse-rate harmonized with the temperature. The question of subphrenic abscess was considered, and on February 5th an x-ray report by Dr. Palmer

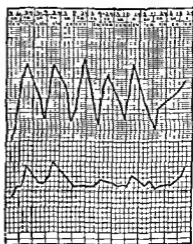
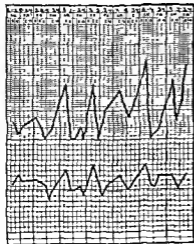
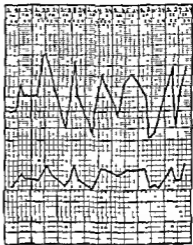
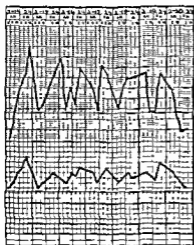
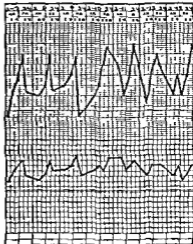
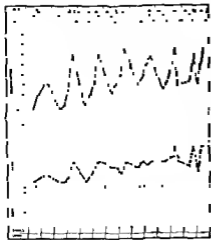


Fig 460

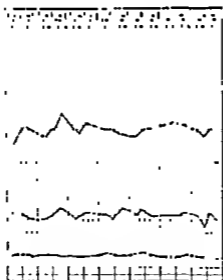
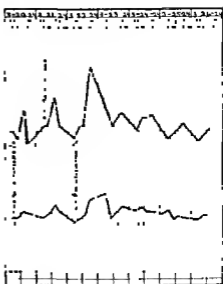
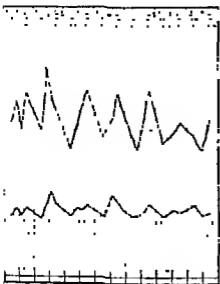


Fig 460—(Continued)

was to the effect that there probably was no subdiaphragmatic abscess. About this time the patient's friends became restless because they felt nothing was being done. After consultation it was suggested that the patient might possibly have a subdiaphragmatic abscess. In view of this possibility we decided that if the patient had multiple abscesses of the liver, an exploratory operation would do him no harm, and if he had subdiaphragmatic abscess, it would be of some value. On this basis an exploratory operation was done February 28th, six weeks after his original operation. The operative findings at this time were as follows:

Small amount of free peritoneal fluid

Liver greatly enlarged, irregular and nodular

Pus was aspirated from one of the liver abscesses.

Smear showed a few diplococci

No growth on blood media

Will say in passing, that on February 13th cultures from the blood of the patient were negative

Following this second operation the chills and temperature continued quite the same for three weeks. Repeated blood-counts showed leukocytosis, with increased polys. Urine examinations were negative

On March 20th Dr Tanaka injected 10 c c of 1 per cent. sodium mercurochrome intravenously. Twenty c c were given the next day, and the same amount the third day. The afternoon of the third injection the temperature arose to 104° F, and then came down to normal, or under 100° F., and has remained so from that time until now—May 5th. Occasionally his temperature would go to 100° F for a few days, but he had no chills after the third injection of mercurochrome

The man today, as you see, has a sinus from the drainage of the appendical abscess. This sinus is very likely the cause of the slight rise in temperature that this man has experienced. His general appearance and condition showed marked improvement immediately following the injection of mercurochrome. His appetite returned, tongue cleared up, and his general strength was greatly improved. Urine examination on March 22d showed

a 2+ indican, but otherwise quite negative. His white count has shown some leukocytosis. Today his count is 16,800, with 68 per cent. polys. Occasionally he has had just a mere trace of albumin in the urine.

We present this case today as an example, we believe, of the beneficial effects of mercurochrome intravenously. Abscess of the liver is generally regarded as uniformly fatal, and the use of mercurochrome was instituted as sort of a last hope. The diagnosis of multiple abscesses of the liver was absolute, thanks to our exploratory operation and the aspiration of pus from one of the abscesses.

We believe that this man is well on the road to recovery, even though he has a small discharging sinus at the site of our original drain.

We have used mercurochrome in only 2 other cases, both were blood-stream infections with furious chills and excessively high temperatures. We have used several injections in each patient without any untoward reactions or complications. Both cases recovered.

Later.—Under date of August 15th Dr. Tanaka reports that the patient with multiple abscesses of the liver is perfectly well and doing his work as a farmer. His sinus is entirely closed.

ACUTE HEMORRHAGIC PANCREATITIS

THIS morning we have 2 cases of hemorrhagic pancreatitis in the hospital to show you. It is seldom in the course of the average surgical practice that one has the fortune or misfortune of seeing 5 cases of acute pancreatitis over a period of one or two years; yet at present we have 2 such cases in the hospital and have had 3 others in the last two years. The literature of the past few years has had numerous articles on hemorrhagic pancreatitis, which for the most part have been reports of one or more cases. Considerable advance has been made in the diagnosis of this condition, yet one is immediately struck with the various symptoms as complained of by the patient and the lack of uniformity of such symptoms.

In a series of 6 cases recently reported by Egger in a rather comprehensive article, he was able to make a diagnosis of hemorrhagic pancreatitis in 4 out of his 6 cases, yet usually this condition is not accurately diagnosed as such until the operation. We frankly admit that in our series of 5 cases, while the condition was mentioned in several of them as a probable cause, the usual diagnosis of cholelithiasis or cholecystitis was made in them. In one the gall-bladder had been removed in 1917 and together with one other was diagnosed as an acute surgical upper abdomen in lieu of gall-bladder disease. That the diagnosis cannot be made with the degree of accuracy that is usual in most intra-abdominal conditions is evident when one reviews the preoperative diagnosis of the reported cases within the past few years. How many cases of hemorrhagic pancreatitis recover without operation and without a positive diagnosis we do not know, yet we feel sure that many mild cases occur only to have subsequent and more severe attacks.

The first case we wish to show you has been in our office on at least two occasions with the same character of pain, though not so severe. A diagnosis was not made and the patient was

told to return should her condition become worse. This patient was awakened in the night with severe cramps in the abdomen which she said were mostly in the right lower quadrant. It was not until the next evening that she began to vomit, but she has vomited almost continuously since. She has had no sleep and has been in great pain even though she had morphin hypodermically for relief previous to admission. Vomiting was constant until the time of her operation. On examination we found the abdomen to be slightly distended, slight rigidity over the entire abdomen, more severe in the lower right quadrant, and general tenderness. Her blood-count prior to operation was 14,400, with a 90 per cent polymorphonuclear count. The urine was negative except for a trace of albumin and some acetone. With this history and the fact that her tenderness was more acute in the lower right quadrant, a diagnosis of probable appendicitis was made. A right rectus incision was made, and immediately upon opening the abdomen bloody fluid was found, estimated to be about 1 quart in quantity. A few small areas of fat necrosis was seen, which immediately called our attention to the pancreas. The pancreas was found to be intensely engorged, much larger than a normal pancreas, and in appearance the entire head was hemorrhagic and black. The pancreas was opened longitudinally, a gauze drain inserted, and the abdomen closed in the usual manner. This patient's temperature returned to normal about the fourth day, with a subsequent slight rise of temperature. There was little drainage from the abdominal wound other than the bloody serum and no excoriation of the skin. This patient made an uneventful recovery, with the exception that she refused food. She complained that even the sight or smell of food would give her nausea.

In this case there was no gall-bladder disturbance. The gall-bladder was thin walled and blue, it was not distended, and the condition could not have been associated so far as we could make out with any gall-bladder condition whatsoever. One point of special interest in this case is the aversion to food that this patient has had following her operation. She absolutely refuses food.

The second patient is a young married woman twenty-nine years of age. She was seized suddenly with severe pains four days before admission. These pains were very sharp in character, rapidly becoming crampy, and were located in the middle upper abdomen. She immediately began to vomit and has vomited almost constantly since the onset of her symptoms. At times she has had little relief, but the pain has been quite constant. On examination the entire abdomen was distended, tenderness existed throughout, but she was more tender over the upper right and left quadrant. There also existed a rigidity of the upper abdomen which could not be made out below. This patient gave a history of definite attacks which had been diagnosed gall-stones. The provisional diagnosis of cholelithiasis was made, however, and the possible presence of acute pancreatitis was suggested. Prior to operation the leukocyte count was 21,000, of which 90 per cent were polymorphonuclear. Urine was negative. On opening the abdomen it was found to be full of bloody fluid with fat necrosis scattered throughout the omentum, and the visceral and parietal peritoneum. Two-thirds of the body of the pancreas was gangrenous. An incision was made into the body of the pancreas, cigarette drains inserted, and the abdomen rapidly closed. This patient's condition was very extreme and for several days we despaired of her life. She has been in the hospital now for some five weeks, having made a very stormy convalescence. She has had almost constant nausea since her operation, and would vomit upon the least ingestion of food of whatever character. The wound has discharged considerable thick pus, but there has been no excoriation of the skin. She is rapidly recovering now and will soon go to her home. This case also illustrates the vomiting which may occur following operations for acute pancreatitis.

In this case the gall-bladder was examined and a few small stones found. Due to the serious condition of the patient the gall-bladder was not removed nor drained, but will probably be attended to at some subsequent date.

The next case which we wish to report was in the hospital two or three months ago. In 1917 her gall-bladder was removed.

told to return should her condition become worse. This patient was awakened in the night with severe cramps in the abdomen which she said were mostly in the right lower quadrant. It was not until the next evening that she began to vomit, but she has vomited almost continuously since. She has had no sleep and has been in great pain even though she had morphin hypodermically for relief previous to admission. Vomiting was constant until the time of her operation. On examination we found the abdomen to be slightly distended, slight rigidity over the entire abdomen, more severe in the lower right quadrant, and general tenderness. Her blood-count prior to operation was 14,400, with a 90 per cent polymorphonuclear count. The urine was negative except for a trace of albumin and some acetone. With this history and the fact that her tenderness was more acute in the lower right quadrant, a diagnosis of probable appendicitis was made. A right rectus incision was made, and immediately upon opening the abdomen bloody fluid was found, estimated to be about 1 quart in quantity. A few small areas of fat necrosis was seen, which immediately called our attention to the pancreas. The pancreas was found to be intensely engorged, much larger than a normal pancreas, and in appearance the entire head was hemorrhagic and black. The pancreas was opened longitudinally, a gauze drain inserted, and the abdomen closed in the usual manner. This patient's temperature returned to normal about the fourth day, with a subsequent slight rise of temperature. There was little drainage from the abdominal wound other than the bloody serum and no excoriation of the skin. This patient made an uneventful recovery, with the exception that she refused food. She complained that even the sight or smell of food would give her nausea.

In this case there was no gall-bladder disturbance. The gall-bladder was thin walled and blue, it was not distended, and the condition could not have been associated so far as we could make out with any gall-bladder condition whatever. One point of special interest in this case is the aversion to food that this patient has had following her operation. She absolutely refuses food.

men acute pancreatitis was found. There was fat necrosis throughout the abdomen. The gall-bladder was distended and full of stones. The patient was in a very serious condition. The gall-bladder was drained, the pancreas was also opened, and cigarette drains were also placed into its head and the abdomen rapidly closed. This patient, however, died within a few hours.

There has been much discussion of late as to the etiology of pancreatitis. The usually accepted theory is that it is a retrogression of bile or duodenal contents into the pancreatic duct. This would no doubt explain the usual case of hemorrhagic pancreatitis, yet one case of acute pancreatitis we have had evidently illustrates the infective type. This young woman of twenty-one years of age was seized with intense pain in the abdomen after having been sick with a cold in the head, a probable sinusitis, for about a week. When she was seen about 1 P. M. her temperature was 102° F, vomiting was constant, and pain intense. She had several chills from the time of the onset of the pain over the next two or three hours, with a rise of temperature immediately to 102° F. No definite diagnosis was made, the working diagnosis being acute surgical upper abdomen. Her white count was 37,000 prior to operation. On opening the abdomen a small amount of bloody fluid was found. There was fat necrosis. The head of the pancreas was very dark red and studded with small yellow spots. It was displaced downward and toward the surface of the abdomen. On opening the head of the pancreas there exuded pus. Drains were placed into the head of the pancreas and the edges of the pancreas were sewed to the parietal peritoneum. Usual closure of the abdomen was done. The temperature immediately went to 104° F. and remained nearly 104° F. during the next five days, when she died. There was considerable discharge from the wound, purulent in character, and also considerable irritation of the skin. This is the only case in which we have had excoriation of the skin following the opening and draining of the pancreas.

Briefly summing up these 5 cases, we wish to call your attention to the fact that in only 2 of them was any associated gall-

bladder disturbance whatsoever. One case contained numerous gall-stones and had an associated acute cholecystitis; the other had a few gall-stones which were apparently doing no harm, as the gall-bladder was not distended and there was no evidence of trouble. In 2 cases there was no evidence of gall-bladder disease whatsoever. The gall-bladders were thin, blue walled, not distended, and apparently had never been diseased. The symptomatology is vague and the physical findings often indefinite. At the present time, of the 5 cases which have just been reported, 2 are living and apparently on the road to recovery, 1 other died following discharge from the hospital a few weeks later with a hemorrhage from the stomach, undoubtedly a part of her pancreatic trouble, the other 2 patients died.

GENERAL PYEMIA FOLLOWING CURETTAGE FOR ECTOPIC PREGNANCY

THIS morning we wish to call your attention to an autopsy report by Dr. W. C. Hunter of the Pathological Department of the University of Oregon. This patient, Mrs. S., died December 6, 1923. We will not burden you with the full report of the autopsy, but will give only the anatomic diagnosis, which is as follows:

Large abscess about fundus of uterus, culdesac of Douglas, and about right lobe of the liver

Pylephlebitis of numerous veins draining region of abscess and tributary to right external iliac, without involvement of the latter vein.

Pyemia.

Extreme acute ulcerative vegetative endocarditis of tricuspid valve—*Staphylococcus aureus*.

Embolism of branches of left pulmonary artery with multiple septic infarcts and abscess in the left lung

Focal fibrinous pleuritis over these areas.

Suppurative arthritis of left sternoclavicular junction.

Multiple petechial and ecchymotic hemorrhages of the skin and pericardium

Marked parenchymatous degeneration of the heart, kidneys, and liver.

Marked acute hyperplasia of the spleen.

Multiple infarcts of the spleen

Multiple abscesses of the kidneys

Purulent pyelitis and cystitis.

Purulent salpingitis and oöphoritis—left.

Purulent endometritis

Acute endocervicitis with erosion

Extreme dilation of the right chambers of the heart.

Acute cholecystitis

Marked chronic passive congestion of the liver.

Multiple acute peptic ulcers of the stomach and duodenum.

Bloody and bile-stained stomach contents.

Localized fibrinopurulent peritonitis.

Fibrinous pleuritis—right.

Absence of right fallopian tube and ovary—operative.

Marked acute lymphadenitis of biliary and mesenteric groups.

Caseous tuberculosis of single tracheobronchial lymph-node.

Marked acute mucopurulent bronchitis.
Recent healed surgical incision of the abdomen.
Slight acute emaciation.
Heart weight, 310 grams.
Spleen weight, 300 grams.
Kidneys weight, 310 grams

This patient was brought to the hospital November 8, 1923. She was twenty-two years of age, married five years; and the mother of 2 children, aged two and three, both normal deliveries. She had always enjoyed good health, with no serious sickness. She reported that her last normal menstruation was August 15, 1923, and that she had not flowed any until October 30th, when she experienced what she called a "flooding spell." Since that time she had had a good deal of severe abdominal pain, especially on the right side. She described this pain as sharp and cutting in character. The day before entering the hospital it was very severe, and she called her family physician at once. He performed a curettage in her home. This was done on the supposition that the patient had miscarried. No evidence of miscarriage was found at the operation, and the patient was then sent to the hospital. When she arrived there was pronounced shock, cold, clammy sweat on the forehead; very pale mucus membranes and fingers, pulse 168, pupils dilated, chest negative; heart negative except for rapidity, abdomen was distended and tender over the pelvis; a doughy mass in the right side of the pelvis, tender and rather indefinite in outline. A catheterized specimen of urine showed low specific gravity, a few granular hyaline casts, occasional pus-cell, and 2+ blood. Hemoglobin was 58 per cent, red blood-count 3,450,000, leukocytes 22,300, 90 per cent of which were polymuclear. A diagnosis of ruptured ectopic was made, and operation performed immediately. A low, midline incision showed a large amount of blood in the abdomen, estimated at 1½ quarts. A ruptured right tube was removed. Abdomen closed without drainage. The pulse of the patient, while in the surgery, remained between 160 and 170. The skin was cold and clammy during the entire operation, which lasted fourteen minutes.

The pathologic report was as follows:

"Middle third of right tube ruptured. There was a mass the size of a small egg in approximal end of tube almost confluent with uterus, round, smooth, and firm. This mass is 4 cm. in diameter, and when opened is found to contain considerable chorionic villi, to the extent that it has a soft, worm-eaten appearance. No evidence of a fetus was found. Microscopic sections from the regions of the tube disclose numerous chorionic villi embedded in the wall of the tube. Decidual cells were also present. Pathologic diagnosis: Ectopic pregnancy with rupture."

At the close of the operation we predicted that the patient would recover provided she could overcome the more than possible chances of infection from curetting.

The temperature and pulse chart (Fig. 461, page 1256) is quite characteristic of the clinical diagnosis of pyemia. You will notice that on November 25th, she had a variation of almost 10 degrees in temperature in four hours. Twelve days after operation the patient complained of pain in the right side of the abdomen, and under the right costal arch. Also complained of a foul-smelling, vaginal discharge. Her temperature, as you see by her chart, had been fairly high ever since the operation. Pulse had been around 120. On the 21st, at 2.30 p. m., she had a severe chill which lasted two hours, and was followed by a temperature of 105° F. These chills were repeated at irregular intervals; generally twice daily until death.

Blood transfusion on the 29th was of no avail.

On November 26th her hemoglobin was 36 per cent., red blood-count 2,080,000, white count 11,000, with 84 per cent. polys.

Wassermann was negative.

Her blood-culture on the 27th showed a hemolytic Gram, positive, long chain streptococcus.

December 1st, five days before her death, the hemoglobin was 34 per cent., red blood-count 1,600,000, leukocyte count 22,300, with 88 per cent. polys.

The lesson which we wish to bring home in the consideration of this case is the danger of the curet. We have had one other


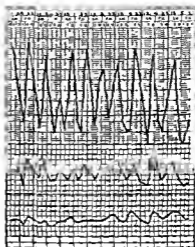
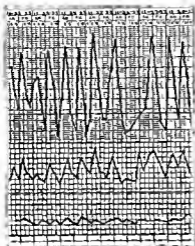
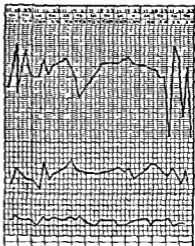



Fig. 461.

case of ectopic pregnancy in which the curet had been used previous to the operation, and the course and results were the same as this case. We feel that the uterine curet is an instrument that is very rarely necessary to use. It is a dangerous implement. The operation of curettage should never be done except under the most careful, aseptic, surgical technic. We are inclined to believe that the late John B. Murphy's advice to his students in surgery was about right when he told them to buy all the curets they could afford, buy a safe, put the curets in the safe, lock the safe, and then throw the key in the river.

The innocent appearing uterine curet was responsible for the widely disseminated accumulations of pus as revealed in this autopsy report.

CLINIC OF DR. CASPAR W. SHARPLES

CHILDREN'S ORTHOPEDIC HOSPITAL, SEATTLE, WASHINGTON

PHYSICS OF SOME OF THE DEFORMITIES OF RICKETS

As one looks around and sees many of the cases of rickets with deformities of one kind or another, the question often-times comes up as to why the peculiar or particular shape is assumed in one bone at one time as against another. This question, perhaps, cannot be answered, but if we take x-ray pictures of the bones of these children after they have been deformed and study them, taking into consideration at the same time the anatomy of the child, chiefly consisting of muscles, the shape of the bone, the position in which it is placed in the body and the particular strains to which it may be placed, the resting position of the child, and at the same time the conditions or relations in which the bones have been placed in the human body, we can perhaps come to some conclusion as to the cause of many of these deformities.

These cases and these pictures that I am going to show you today should bear this out. It has been said that the causes of the forms of deformities of rickets are, first, station; second, muscular tonus; third, position; and fourth, atmospheric pressure.

In order to have an opportunity for these different forces to act we have to have primary changes occurring in the bones. Bones under ordinary circumstances are supposed to have sufficient strength to bear the weight of the child at the individual age. Nature has in every way endeavored to meet all the requirements of the human body at the individual time of life, and it is only when something has gone materially wrong that nature falls down in her endeavors. So, under ordinary circumstances, our bones should have the normal positions and the normal strength. Anything that reduces the strength of these

bones, of course, predisposes to a deformity. If we have a spongy extremity and the child stands straight and fair, there would be a tendency toward flattening of this extremity; if we have a spongy extremity and the child stands at an angle, the tendency would be to flatten one side or the other.

So the first thing we see, if we look at this picture (Fig 462) that I have taken from Jones and Lovett's book (along with some of the others that follow), is the four stages of rickets. At the extreme right you will notice there is very little development of bone tissue, that the distal extremity of the femur and the proximal extremity of the tibia are very irregular in shape, and that they have a soft, spongy-looking mass taking the place

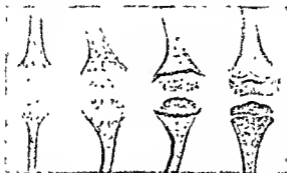

Fig. 462 —(From Jones and Lovett, Orthopedic Surgery, Wm. Wood & Co., Publishers.)

of what would be the bone with a comparatively dense center of ossification. In the next one to the left we see these changes have progressed a stage farther, the center of ossification has become enlarged, the spongy or soft mass has decreased in size, and the general bone is darker. The third one shows a little more progress, and the fourth shows a healed diseased bone.

If you compare these bones as they appear in this diagram to an ordinary picture of a child in a healthy condition it will be seen that the extremities of the bones themselves are very much enlarged. Take a portion of the long bone that has been affected with rickets and you will find that there has disappeared from the bone, if we make an x-ray picture, a certain de-

gree of the opacity, and this disappearance of opacity demonstrates that there has been an absorption of some of the matter which, in this instance, is the inorganic matter from the bone, leaving proportionately a larger quantity than of the organic matter. There is an actual decrease in the thickness of the bone between the plates. From this we can see how easy it is, then, for changes to appear in the shape of these bones that are soft. By and by, though, we have the healed type of bone and, as we get the healed type, in certain areas there is an increase in the deposit of lime salts, and the consequence is, the bone has become more brittle.

If we compare the condition of these bones to any material that is used for support we find somewhat of an analogous situation. Take iron, for instance, as it is used in building, and you find, if you want to get a certain degree of stability with a minimum amount of weight, that the iron is more or less expanded. So far as station goes, there is more security in an iron pipe 10 inches in diameter than in an iron pipe 4 inches in diameter, even though the exact weight of the two pipes were just the same. The same thing we find in our bones. Where we need stability our bones are large and massive, and so in our extremities we have this same thing, and at the point where the greatest degree of stability is needed or the greatest amount of power or weight is to be applied we have this expansion of the end of our bones. For instance, in our femur, besides the amount of calcareous matter in the extremity, there is a large amount of cancellated matter between the two eburnated plates of the bone. If this is absorbed or if the shell upon the outside of it is broken, the bone is more liable to change its shape. So if we look at the next picture and the two to follow we will find these changes made very manifest.

In Fig. 463, which is an illustration of the first stage of rickets, we find a very small quantity of eburnated matter showing in the bones, and what does show is upon the edges or the periphery, so that the middle portion of the shaft of the bone is quite transparent. In the next picture there is a larger deposit of organic matter in the bones. The bones themselves appear to be a little



Fig. 463.—(From Jones and Lovett, Orthopedic Surgery, Wm. Wood & Co., Publishers.)

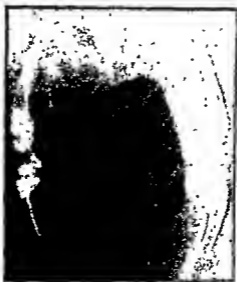

Fig. 464.—(From Jones and Lovett, Orthopedic Surgery, Wm. Wood & Co., Publishers.)

darker. Still the rarefaction is manifest upon the inside. Perhaps in this picture you can realize or at any rate imagine you can see that there is an increase in the amount of eburnated tissue. In Fig. 465 you will notice still apparent a rarefaction of the bone. On the inside of the convexity there is an increase in the amount of the heavy shadow of each of these bones. If you will look at the femur you will see that this density is upon the inside. If you will look at the tibia and the fibula you will see the bow is to the outside of the exterior of these bones; also, if

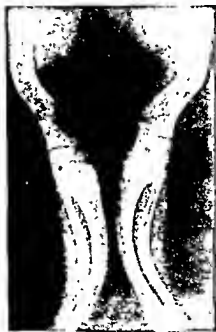

Fig 465.—(From Jones and Lovett, Orthopedic Surgery, Wm Wood & Co., Publishers)

you will look again, you will discover that the bow in the upper extremity is outward and that the bow in the lower extremity is inward.

Figure 466 shows a healed bone which you see is quite dark due to the deposit of an extra amount of lime salts. This bone has become more brittle than any of the others. When the bone has reached the last two stages nature has been able to fortify herself to prevent further increase of the deformities, and she has fortified herself by causing this extra deposit of lime salts upon

the inside or concave portion of the bow. To explain the process by means of which nature has elected to deposit this extra amount of bone in the manner in which she has is very difficult or impossible. So much for these general considerations.

We show you, then, these children. You will notice in the first child a very remarkable bowing of the legs (Fig. 467). An x-ray picture in this case shows the deformities in the femurs corresponding very much to those in the upper part of Fig. 465.

Let us take the femur and examine it, also examine the position in which it is placed in the body (Fig. 468). You will



Fig. 466—(From Jones and Lovett, Orthopedic Surgery, Wm Wood & Co., Publishers)

see, if you look at this bone first, that the head is offset at an angle at the end of the neck a couple of inches away from the main center line of the shaft of the bone. You will also notice that on the lower extremity there is an expansion of bone, and the center line of this lower expansion is practically under the center line of the head of the bone. So far as the shaft of the bone goes, if you will notice it carefully, it is not perfectly straight, but there is a slight tendency to an outward bow. If you look at Fig. 473 a little farther on, which I have reproduced

from Jones and Lovett, you will notice that when the bones are placed in position there is a very marked space to the outer side of a line drawn directly from the head to the center of the condyles. This, then, has a tendency to increase the amount of outward bowing that we have in the bone. In other words, we have a natural curve in the bone which is exaggerated by the position of the bone. If you turn this bone sideways and look at it you will also notice that there is a slight anterior curve, so that at no time or in no position do we have an abso-



Fig. 467.

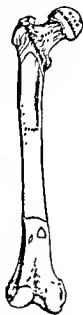


Fig. 468.

lutely straight bone like a piece of straight iron pipe extending from the pelvis to the inner joint. Let us also remember that we have certain muscles coming from the pelvis on to the femur and certain muscles coming from the pelvis down to the bones below. The hamstring muscles go from the pelvis, pass over the femur without any attachments, and are fastened to the upper part of the leg in place of to the thigh. The adductor muscles come from the pelvis to be fastened to the femur, varying in length, size, and strength from the short to the long muscle, and also varying as to the extent of their attachment and the

position of their attachment, so that the long muscle is fastened low down upon the shaft of the femur

Let us take this into consideration: first, the normal station. The illustration I have shown you will give you an idea of that station. We have a weakened bone. We have a natural outward curve increased by the shape and position of the bone. We have no particular bracing upon the inside of that curve. We have a weight more or less constantly pressed upon the top



Fig 469

of these two bones that have been so softened by disease that they are not capable of resisting this pressure, and the result is that this weight tends to increase the natural lateral curve of the bone. The same thing would apply to the anterior curve that we see, and it is not uncommon, as you know, in rickety cases with bow legs to find them show a lateral curve and anterior curve in the same bone. Suppose, again, that we have a softened bone, the child was never able to stand upon his feet, his legs were kept more or less straight. We have a rubber

band fastened from the pelvis to the bones of the leg on constant tension. It is easy to see that the tendency then would be to double this bone up with an anterior convexity (Fig. 469). Suppose, likewise, we had our pelvis fixed, had a soft bone fastened at the head, and we had a rubber band going from the pubic portion of the innominate to the lower portion of this bone with a constant degree of tension. We could see then that there would be a tendency if the head were fixed to draw the lower portion of the bone up toward the pelvis, which at the same time would make a curve in the bone by drawing the lower portion in toward the central line. While, perhaps, this is rather far fetched in this particular instance, still the tendency of the muscles to produce this modification is not negligible by any means. If the adductors did not function, our knees would spread apart. So I would say that for an ordinary bow-leg with a deformity above the knee the three causes of the deformity are: first, the shape of the bone; second, the weight above the bone; and third, the muscular tension.

If you will refer back to Fig. 466, which we are using for the purpose of avoiding the use of too many plates, you will notice there is a very marked lateral curve in the tibia and fibula with the convexity outward. This represents the ordinary common type of bow-leg. In bow-leg we have a separation of the knees. We have the bend occurring in the femur according to the position which we described last. Then, in all probability, to get the feet properly under the trunk there would be a tendency to pull the knees out, and if we pull the knees out in order to get our feet under our body we are going to have our feet placed in the center and the completion of the curve then has appeared in the femur by means of a like curve in the tibia. In other words, if we have a crooked femur with the bend out, the tendency would be for one foot to be placed across the other, so that if we only had the bend in the femur and the child were walking, it would walk very much in the position that we have people walking in spastic paralysis of the lower extremities. The child naturally places the feet one upon either side. This, then, throws the knee out, and the knee being thrown out the weight then

comes upon one side of the articulation and produces a curve in the tibia and fibula corresponding to that in the femur. When the curve develops in the femur in the ordinary run of cases you find also a curve developing in the tibia and fibula. The feet then are the only things brought under the articulation of the head of the femur with the pelvis, and we have this marked outward curve. Also recall the soft condition of the extremities of the two bones that go to form the articulation of the knee and the necessity of endeavoring to keep the line of articulation practically parallel with the surface of the earth, and also the

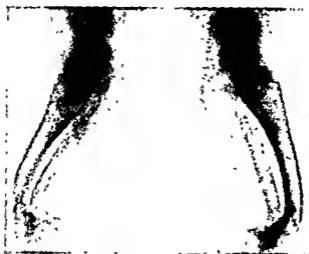

Fig 470.

necessity of avoiding a hiatus at the outer portion of the articulation, and also keeping in mind the fact that most of the pressure would naturally come upon the internal condyle of the femur and the internal portion of the head of the tibia, that the softened substance in these two places would be compressed, and that, if it were not for this compression, it would be necessary to have an elongation either of the external condyle of the femur or the external portion of the head of the tibia, probably both of these things occur. In deciding as to the proper method of correcting the deformities in the legs, we have also to take

into consideration the changes that have occurred in the inner portion of the joint and in the outer portion of the joint, and they are points that are very vital, for if the correction is made early, that is, while the bones are soft, one method can be more efficient than the other, or if the correction is made late, when the bones are hard, probably only operative procedure will correct the shape of the bones, while it is unfair to suppose that such an operative procedure would in any way vary the articular expansion at the ends of the two bones.

You notice, also, in this child, pictures of whose legs I am showing you (Fig. 470), we have another curve which is an an-



Fig 471.

terior curve. *x*-Ray pictures of the bones of the bow-leg shows this anterior curve occurs in the lower portion of the bone. If you look at this picture (Fig. 471) of the tibia I think perhaps you can find an explanation or the reason that all these bows at the lower end of the tibia come at practically the same place. The tibia is practically a double truncated cone joined together at the smallest place about 4 inches above the lower extremity. The base of the upper cone is made by the upper articular extremity and the base of the lower cone by the lower articular extremity. From each of these points the size of the bone

tapers to the above-mentioned point. Also, if you look at the bone and take a pair of calipers, you will find that the bone is thinner in a lateral position at this point than at any other point of the bone. You will notice in many of these plates that at the point where we have the anterior curve there is always a marked angulation laterally of the bone.

If you will refer to Fig 472 you will notice what a marked hooking there is of the lower extremity of the bone. In the il-



Fig 472

lustration that I am showing you of this child with feet turned out (in order to make the deformity appear more exaggerated) you perhaps can imagine you can see the body of the gastrocnemius and soleus muscles, the tendon from which comes down to the os calcis. Take, again, the illustration that we used before of a rubber band coming from the knee to the foot with a varying degree of constant tension. We have a soft tibia and we have a particularly thin place in the tibia. The rubber band draws the two ends of the bone together and has a tendency to pro-

duce an exaggeration of the natural curves that exist in this bone. In our case the rubber band is the gastrocnemius and soleus muscle fastened at one end to a bone directly, and at the other end to the bone by the intermediation of a tendon. This is the strong muscle upon the leg. We do not see posterior curves in the tibia and fibula. I believe our elastic band made of muscles is sufficient to produce the curve in the bone if it were sufficiently soft, regardless of any superimposed weight. If we add to this the weight of the body which the bones are required to bear at irregular intervals, we have the two mechanical features that enter into the causation of this deformity.

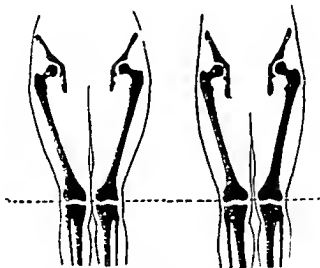


Fig. 473.—(From Pfeiffer.)

To go back to the illustration (Fig. 473) of the articulation of the femur with the pelvis and also the articulation of the condyles of the femur with the bones below, I think you will see one other fact that I have not called to your attention before—that is, there is a prolongation of the inner condyle, or perhaps you can see that the internal condyle is longer than the external one, which on account of the position of the bones in the body is necessary in order to have the line of the articulation run parallel to the surface of the earth.

You will notice that the length of the condyle in the female is more marked than it is in the male, due to the fact that the

heads of the femur are separated more widely in the female than in the male. If for any reason we have softening of our bones and a change in the position of our bones, we have changes likewise occurring in the length of this internal condyle so long as the extremities are soft.

Take now the consideration of knock-knees in the place of bow-legs. As we ordinarily stand there is a certain amount of space between the knees. If we have a softening of these condyles and a softening of the tibia, and the knees for any reason approach one another more closely, we will find that the softened matter upon the outside of these two articulations is more or less compressed, or, in other words, the external condyle becomes shorter and the exterior part of the head of the tibia becomes pressed down more toward the foot. If there were no compensatory growth of the bones we would find there would be a separation of the internal condyle of the femur from the interior portion of the head of the tibia and nothing to fill the space. It would be very much like we would take a green stick and attempt to break it. The outward portion of the stick would break and separate and the inner portion would be somewhat more compressed. In order to overcome that nature has provided that the softened matter upon the internal portion of the condyle grows down, and as it grows down it meets the articular surface below. Perhaps this could be expressed by the lack of resistance to the growth of the bone. Such change in the growth of the bone naturally produces an approximation of the knees to one another, and if the knees then grow toward one another we have the condition which we commonly speak of as knock-knees. Knock-knees do not exist by themselves as a change in position, but we have other changes in the shape of the bone, and I am showing you here this group of children all in one family possessing a rather remarkable collection of knock-knees (Fig 474). I do not think it is too much to expect you to be able to see that there is a change in the shape of the femur, a change in the position of the knees and a change in the shape of the tibia. Nor is it asking too much to ask you to realize the appearance of the increase in the length of the internal condyle.

While the children are before you I want to call your attention to the position these children have assumed in order to stand. Notice the boy marked "Wilkins" and the child marked "Eugene" stand with their knees locked, the right knee in each instance being placed in front of the left; or, in other words, the internal condyle of the right side is hooked over and anterior to the internal condyle on the left side (Fig. 474). When the knees are bent together and the internal condyles are elongated and we try to stand the child straight with one condyle in the same plane as the other you will notice from the position of this child that




Fig 474.

the feet would have to be spread out a great deal more than they are at present. Not only would that have to be accomplished, but, if we look at these children, the feet are not placed straight in front as in the child marked "Dewey," but the feet are placed at an angle. In other words, the toes are everted, and the toes are everted entirely in proportion to the amount of deformity at the knee and the inability of the children to place the knees in the same place. If we take this boy "Wilkins" and place his knees in line laterally, you will notice how much more eversion there is in his feet and how much farther his feet spread apart.

If this be the case and you have this boy walk, you will notice that he has to waddle to a certain extent, and the reason is apparent. He has to throw his one knee out to keep it from interfering with the other. If he had to move his legs straight forward the internal condyles would constantly strike against each other. Consequently he has to assume this waddling gait for one internal surface to pass the other.

These children in order to stand in any comfort have to squat (Fig 475). If they lock their knees to hold themselves



Fig 475

up, they likewise squat down to a certain extent, so that the knees are not placed straight under the trunk, but are placed anterior to the general lateral plane of the body. We have these children that we see here in front of us standing in a squatting position with the knees locked and their feet spread wide apart in order to maintain their station.

As the primary cause the bones are soft. When there is any disease of the bones there is some degree or character in the change of posture. We have a superimposed weight upon the femur. The knees are placed farther in than they belong. There

is a natural curve of the femur outward, so then we have an outward curve of the femur. I have also called your attention to the fact that we have a natural anterior curve in the femur. The consequence is then that we have an increase in the anterior curve (Fig. 476). I have no later x-ray picture of these children to show you, but from a lateral view you will see there is a marked anterior curve in the femur and high up in the femur an outward curve. These changes cause a good deal of difficulty in correcting the position of the legs by operation. When the bones are



Fig. 476.

sufficiently soft that should be a warning to us that we should correct them by manipulation and pressure apparatus, for the reason that we have no operative procedures to correct the shape and length of the condyles of the bones that are feasible. We may be able to bring the bone into line by means of an operation. Whatever operation we do produces an artificial increase in angulation at that point in place of gradually overcoming a vicious curve and it does nothing toward changing the length of the condyles.

We say that operative interference should not be done upon rickety bones that are not sufficiently hard to stay in the position we place them. Take, then, this older child, marked "Wilkins," whose bones are very stiff and firm. Any operative interference there would tend, of course, to take a part of the curve out, place the knees in a different position from the one they are now in, but if the solidification of the bone or condyle has become sufficiently marked that they are not going to give to pressure,

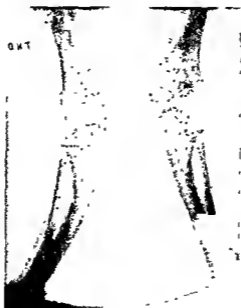

Fig 477

then we have not much opportunity to accurately straighten these legs. Merely straightening the femur does not overcome the changes that have occurred in the bones and joints themselves.

Before looking at the changes in the tibia, look at this picture of the tibia (Fig 471). I want to call your attention to the fact that we have two lateral curves in the tibia. If you look at the crest of this tibia you will see at the upper extremity the natural curve in the crest, consequently, a natural tendency in

the bone itself to bend and for the convexity to be inward, just as the crest of your tibia has marked in it an inward convexity. Down in the lower position this curve changes, changing rather markedly at the point of the junction of the two truncated cones, and there the convexity is outward.

An ordinary curve in a knock-knee case would be about as you see it in Fig. 477. It appears that in the upper portion of the bone there is a marked inward convexity. I think also you will notice in this picture a marked prolongation of the internal condyle. This convexity you have here can be explained, first, by pressure, and second, by the natural curve of the bone in the upper portion. Also you will see there is practically no curve in the lower portion of the bone. If you take the next picture you will see exactly the same positions, but you will also see that in the lower portion of the bone (Fig. 470) there is a hooking in of the bone itself; in other words, a bowing of the bone, so that we have the convexity outward in place of inward, following much the same curve as in the lower outward one and hooking at the point where we have the junction of the truncated bone. So then position and natural curves of the bone are responsible for the two curves in the lower portion.

The anterior curve is also present (Figs. 475, 476). You will notice this child as he stands has a bending forward of the lower portion of the bone. As he stands also he stands with support. If you will take an *x*-ray picture laterally you will likewise find an anterior curve, so that in many of these bones of the lower extremity in knock-kneed children we find three curves: a curve in the upper portion of bone with convexity inward; a curve in the lower portion of the bone with convexity outward; another curve in the lower portion with convexity anterior.

I want during this lecture to show you this *x*-ray picture (Fig. 478) of the result of an osteotomy in one of these cases, and also to call your attention to the fact that as a result of the muscular tonus of the muscles on the back of the leg there is apparently a shortening of the muscle itself. This child had an osteotomy done upon it; the leg was placed in a cast; during the operation there was no relaxation work done upon the muscle

The bend in the lower portion of the tibia is the same under ordinary circumstances in each leg. If we look at this picture we have one foot lying on top of the other. The external portion of each foot is toward the surface upon which the child is resting. The right leg we take for granted has a bow in it, the left leg is resting in that bow. The curve in the left leg is an external bow; so, likewise, if the position of this child accounted for those deformities below, we would have an external bow in the right and internal bow in the left, which condition, as you know, does not exist. So far as I go, I have not seen one presented to this clinic of that type. I have no doubt that unusual circum-




Fig. 480.

stances might arise in which we might have the reversal of the deformity, it would be purely problematic. If you notice the upper portion of this child's body, there is a possible deformity in the humerus and positive deformity of the radius and ulna.

Let us take this child with a deformity of the upper extremity. At the same time I will show this picture of the forearm. Looking at the child it is perfectly evident that the bones of the forearm are not straight (Fig. 480). Looking at this picture it is more evident, and you will notice the marked backward curve of both the radius and the ulna. If you look at these bones you will notice when the radius and the ulnar are

placed together there is a posterior convexity. The natural curve, then, is concavity forward (Fig. 481).

Notice also in this picture the extreme enlargement of the distal extremity of both the radius and the ulna.

If you refer back to the picture of the child sitting, you will see the child is sitting, resting more or less on both hands. If you will also refresh your mind of the anatomy of the parts you will remember that all the muscles upon the anterior part of the forearm arise from the upper portion of the radius and the ulna,

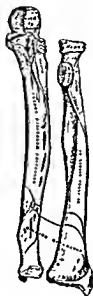

Fig. 481.

or from the condyles, both internal and external, of the humerus, passing to their attachments to the wrist and hand. The tension band then that we have practically extends from above the elbow, upon the anterior portion, to the wrist and below. If the bones, then, were left perfectly free with elastic band from one portion to another and were sufficiently soft, it is easy to see we would have a deformity such as you see here.

If you take a man with a hemiplegia, if you take a child with paralysis in which the posterior group of muscles is involved, and you get a contracture, you will notice the hand is always bent forward. This is more easily explained when we

have paralysis of the posterior group only. When the spastic condition occurs in the hemiplegia the supposition is, of course, that both the anterior and posterior groups of muscles have been paralyzed equally, but the spasticity that occurred was more marked in the anterior group, and you will find in all those cases that the hand is bent forward upon the wrist and the fingers are contracted in the palm of the hand so as to make a fist, demonstrating that the muscles upon the anterior portion as a group are stronger than the muscles on the posterior portion. I do not think, then, there is anything unfair in attributing this deformity in the forearm to the contraction of the anterior group of muscles. I believe, also, that the character of the work to be performed by the anterior group demands more power.

When we endeavor to correct or prevent contractures we place a cock-up splint upon the anterior part of the arm in order to prevent their full activity. The deformities that occur in the humerus, I think, bear the same relation.

The next deformity we would consider in the long bones is that of the clavicle. I present to you the picture of this child which I think shows a very marked deformity of the clavicle. I also present to you a clavicle itself. It is an S-shaped bone with an anterior curve on the inner portion, a posterior curve on the outer portion, and somewhat of a curve on the upper side in the middle portion. The deformity that we show you here shows an increased anterior curve, an increased upper curve, and a posterior curve not very apparent. I think this gives us the most interesting speculation that we have in the deformities of rickets. The subclavius muscle is inserted along the under portion of the clavicle out to and beyond the middle. The sternocleidomastoid muscle is inserted upon the inner portion. The only bony articulation that the upper extremity has with the trunk is in the inner portion of this bone and the sternum. The bone that prevents the shoulder from being approximated more closely to the chest or the ribs is the clavicle. The upper extremity is completely hung, as far as bones go, on the distal extremity of the clavicle. If we fracture the clavicle beyond the insertion of the sternocleidomastoid muscle, the shoulder drops

because there is no muscle beyond that to hold the end of the clavicle up. The subclavius muscle has a downward pull, the sternocleidomastoid muscle has an upward pull. By analogy, then, if we have a soft bone, the sternocleidomastoid, being a strong muscle and more or less constantly in tension, we have an upward pull inside the attachment of the subclavius muscle and the end of the shoulder would have a downward pull. The natural supposition would be, therefore, that we would have an increase in the convexity of the clavicle at its inner portion, that is, at the portion between the insertion of the subclavius below and the sternocleidomastoid above and the articulation of the sternum. Upon the front the pectoralis major muscle goes from the ribs to the anterior portion of the humerus. Upon the back the latissimus dorsi goes to the posterior portion of the humerus; the serratus magnus goes to the scapula, the rhomboid muscles likewise go to the scapula. The natural tendency for them is to pull the arm or the humerus toward the ribs. Some of them act directly; some of them act in an oblique line; some of them act through the intermediation of the scapula, but in a way all these muscles are adductors. They are not adductors in the sense that they are pulling the head of the bone or the external angle of the clavicle directly into the trunk, but the fulcrum or the fixed part is the scapula and the clavicle to which they are attached. This adduction is more or less constant and in practically all activities is present.

We have an S-shaped bone with two curves in it. We have a soft bone. These muscles constantly pulling the humerus and its head against the glenoid fossa, the scapula in which it is placed being fastened to the end of the clavicle by means of ligaments, makes, then, pressure upon the end of the bone which, of course, would tend to aggravate the two existing curves if the bone is softened sufficiently to permit this.

Another deformity that is easily explained in the bones is the so-called Harrison curve, which is a curve around the ribs. We know that the tendon of the diaphragm is placed in the middle of it. The origin of the muscular fibers of the diaphragm is in the periphery of the chest upon the inside of the ribs. The in-

sertion is in this tendon. There is nothing we have that works more regularly or constantly than our diaphragm. Its contraction occurs often. The center of it is fixed, so that there would be a tendency, if there be any softening of the ribs, to draw the ribs toward the tendon of the diaphragm at the same time that the central portion descends. This constant action then in softened ribs would produce the so-called Harrison curve.

I also have seen an illustration the object of which is to explain the so-called beading of the ribs. This is the only place I know where atmospheric pressure has a marked influence in producing a deformity of rickets. The costal cartilages are fastened or articulated at the distal extremities with the ends of the ribs. If for any reason we have any internal displacement of the distal ends of these cartilages we are going to have an elevation on the outside of the end of the rib and an elevation upon the inside of the costal cartilage. Consequently, we have what we speak of as a beading. There is just one thing, under ordinary circumstances, to do this and that, is the pressure of atmosphere compressing the chest anteroposteriorly, which is not an uncommon appearance in rickets.

CLINIC OF DR. GEORGE W. SWIFT

CHILDREN'S ORTHOPEDIC HOSPITAL, SEATTLE, WASHINGTON

VARIATIONS IN CEREBROVENTRICULAR STUDIES

SINCE Dandy, of Baltimore, gave to the medical profession the technic for the insufflation of the cerebral ventricles a great many workers have used this method of diagnosis of intracranial lesions. There has been, however, considerable discussion regarding its value and the danger of the direct insufflation of the ventricles after a trephine of the skull has been emphasized by many writers; it seems to be used more or less as a last resort, rather than routinely, in diagnostic work.

It is a well-known fact that in brain abscesses and in brain tumor cases where the pressure reaches a certain point sudden death may occur. Everyone who has had many cases of such cranial lesions has had that experience, and yet in those cases when air has been used the death is attributed to the use of air. This, perhaps, accounts for some of the confusion regarding its value. Perhaps some of the fatal cases would have resulted fatally, even though air had not been used. However, when one death occurs after the direct injection of air it makes one question seriously the value to be placed upon such a procedure. It is not even necessary to have a death; a severe shock following the release of intraventricular pressure is sufficient to dampen the enthusiasm. It was because of such occurrences that I was prompted to abandon the direct puncture of the ventricle and adopt the lumbar puncture. In Dandy's early work he discussed the technic of insufflating the ventricles by the spinal puncture method. Later Bingel reported a large series of cases in which he used this method rather than the direct puncture.

The value of air in cerebral diagnosis depends upon two factors—a comparatively safe and reliable technic and a proper

interpretation of the films. Since I have been using the spinal approach I have had practically no serious shock, the patients have complained of little or no after-effect, the knowledge obtained has been vastly more important, and the films have been equal if not better than those obtained by direct puncture. This technic has been used at various hospitals, and extensively at the Orthopedic, where studies have been made on children with hydrocephalus, congenital spastic paraplegia, epilepsy, cerebellar aplasia, brain tumors, mental defectives, cysts, and traumatic lesions.

Briefly, the technic that has been evolved is as follows:

Technic.--In children a general anesthetic is given about 11 o'clock in the morning. (No breakfast given.) This time is chosen because it is absolutely essential that the stomach and alimentary tract be fairly empty. The patient is then placed in the upright position with the head slightly forward, the lumbar region prepared, and the needle inserted in the fourth interspace. A special needle is used to prevent loss of fluid and the manometer reading made. Five c c of fluid are then removed and 5 c c of air injected; after a short interval if there is no change in the pulse or respiration 5 c c more of fluid removed and 5 c c of air injected; again, after a short interval, this is repeated until finally 20 c c. of fluid are removed in all and 20 c.c. of air injected. The patient is then kept in the upright position until the anterior posterior films are made. These are made immediately following the last injection. The film is then viewed and if normal in appearance the lateral pictures are taken. If the air enters only one side, the child is laid upon the table with the side containing air down, and after a few moments another anteroposterior film is taken to see if the air has changed to the opposite side, which frequently is the case. Then the lateral stereos are taken. In adults the same technic is observed except it is done under local anesthesia with the patient on a chair before a table, the forehead resting upon the folded arms (Fig 482). After the first air is injected the patient is requested to state where he feels pain, and usually he will note the progress of air toward the ventricles. When it enters the lateral ventricle

he will complain of pain behind the eyes. There is considerable shock immediately following the injection of air under local anesthesia in adults. A normal case will have considerable sweating and pallor, but rarely, if ever, faint. A syphilitic case, on the

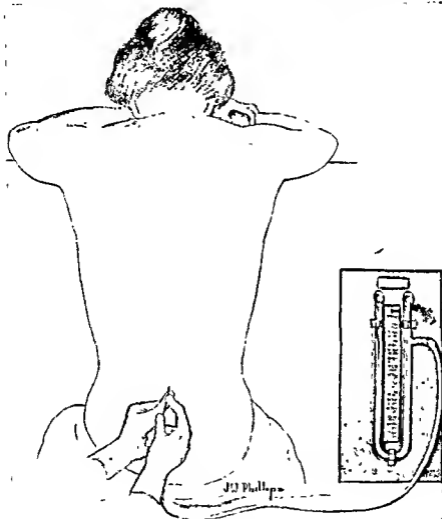


Fig 482.

other hand, will have practically no sensation. Usually in epileptics the shock is more severe than in normal cases. Women seem to stand it better than men. It is not uncommon to have a nervous person apparently faint before any air is injected. For this reason it is best not to tell the patient too much about the symp-

toms, but rather ask them to note any change that takes place. Following the x-rays the patients are placed in bed, an ice-cap to the head, and they are not given anything to eat that day. The pain usually subsides very quickly in children, they are up and about the same afternoon or evening, while in adults it persists for a longer time and they usually remain in bed until the next day. The amount of air need not be over 25 c c., however, in cases of syphilis upward of 45 or 50 c c. can be injected. These



Fig 483—Anteroposterior view, normal

cases usually show an enlargement of the ventricles and the diagnosis can almost be made during the injection. In spastic paraplegia it is a good plan to go very slowly with the injection. These cases seem to have a severe reaction. In early hydrocephalus 20 c c. is a sufficient amount of air, in late hydrocephalus 10 or 20 c c. is sufficient to diagnose the type of hydrocephalus, which, after all, is about all one can accomplish in these cases.

This series of cases will be used to emphasize various points in the variation in the size, shape, and position of the ventricles

The Normal Case.—In a normal case where the air has been injected in the spinal canal and the x-ray films have been properly made it is not difficult to interpret the films. As one views in the screen the anteroposterior film (Figs. 483, 484) the first thing to note is the position of the central butterfly shadow which corresponds to the vertical outline of the two lateral ventricles and the third ventricle. Using the technic, as outlined above, the shadows should outline approximately 1 c.c. to the right and left of the midline for each ventricle at its widest point;

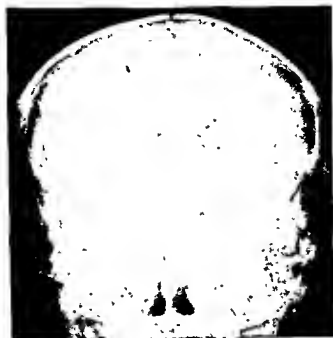

Fig 484—Anteroposterior view. Normal right; slight dilatation left.

approximately 2 cm. in length from above down; the curved outer edge of the shadow corresponds to the mesial surface of the optic thalamus on either side, while the upper slanting margins correspond to the roof of the lateral ventricles on either side; the third ventricle in the midline should be approximately 5 mm. in width; as you glance upward toward the vertex an irregular dark line appears in most cases, this apparently corresponds to the separation between the two hemispheres, and is important because its position usually marks the center of the

vertex, and in some this appears to be the suture line, however, in some anteroposterior and lateral stereo films it would appear that air seems to accumulate at this point between the two hemispheres, in children the suture line shows distinctly and gives one a good point to designate the midline of the vertex. Accumulations or pockets of air on either surface of the cerebral hemisphere show as a black line just under the skull. At the point corresponding to the frontal sinuses a black shadow corresponds to the chiasmal cistern and frequently a butterfly

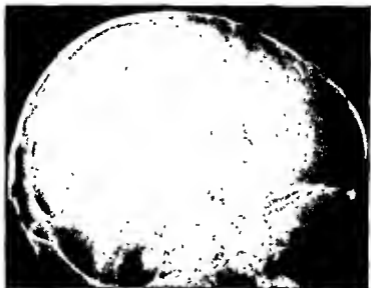


Fig 485 —Showing lateral view nearly normal.

is seen at this point also. In the stereo anteroposterior films this butterfly is sometimes beautifully outlined in the region of the pituitary, a line drawn from the septum of the nose upward to the suture line in the vertex should bisect the two butterflies, and in a normal case the two sides should be symmetric. A film made six hours after the injection of air should show the air practically absorbed in normal cases

In the lateral view (Fig 485) of the normal cases the thickness of the skull is noted; the character of the mastoids; the size of the pituitary; the development of the sphenoid and

frontal sinuses, after which a study of the air in the ventricles is made. The anterior horn usually is fuller than the posterior, in fact, the posterior horn comes to a fairly marked point where the lateral ventricle bends again to run forward into the lateral wing; this angle corresponds roughly to the shape of the angle of a chicken's wishbone; if you hold a wishbone of a well-developed chicken in the horizontal position, with one wing pointed downward at an angle of 45 degrees, you will have roughly the proper position of the lateral ventricles as depicted on the film. In the normal case the thickness of the anterior horn should be approximately 1 cm., club shaped; the posterior horn about 1 cm., also slightly club shaped; the line between about $\frac{1}{2}$ cm., with the convexity upward; the lateral wing 1 cm. and club shaped, with its curve downward; the convexity of the lateral ventricle undoubtedly corresponds to the convexity of the optic thalamus and lenticular nuclei.

When the ventricles enlarge the width of the shadow in the anteroposterior film increases relatively at the expense of the outer line, that is, the shadow encroaches on the area of the optic thalamus; in the lateral film the anterior club appearance increases and the anterior tip of the lateral wing increases, while the posterior tip remains approximately the same.

Congenital Deformities.—One of the commonest irregularities in the outline, as found in children suffering from convulsive seizures of the epileptic type, from spastic paraplegia, as in Little's disease, from asymmetry of the face, hands, and legs, and all the classes of cases showing variations of these symptoms, is a variation from the central position of the shadows of the anteroposterior film. These may be grouped roughly into, first, congenital defects of the right or left cerebrum resulting in a retraction or shoving beyond the midline of the ventricular system. On the film, this shows as in Fig. 486. This is a case of a young girl suffering from a congenital defect which will be described under Case I. A study of this film indicates one of two things, either the ventricular system has been shoved over by a tumor mass on the left side or drawn outward by contraction on the right. While this is an exagger-

ated condition in this particular case it is not uncommonly found in these studies. While congenital defects have a tendency to draw the ventricular system to the side, it must be borne in mind that the same clinical picture may be present and the same ventricular shadows shown in cases of angioma undoubtedly due to birth hemorrhages which have a tendency to shove the ventricular system to the opposite side. It is not easy to differentiate between these conditions, either from the



Fig. 486—Case I. Showing displacement to the right, with dilatation of the right lateral ventricle.

clinical picture or from the ventricular study. Congenital defects may be associated with an angioma which developed at the time of a birth hemorrhage, as in Case II and as shown in the illustrations for that case. There is no question but what there was a birth hemorrhage in this case, resulting in atrophy of the cortex of the brain as well as the development of the angiomatous condition of the blood-vessels in the arachnoid. In this case an operation on both sides revealed the true pathology and it showed the reason for the displacement of the ventricular

shadow. This was due to the normal growth on one side and a failure to develop normally on the opposite side, which permitted the normal side to extend beyond the midline and occupy the space which should have been occupied by the contracted side. This undoubtedly was true also in Case I, as shown by the illustrations. Case III illustrates the large angiomatous mass shoving the ventricles beyond the midline. Before air was used in this case the symptoms pointed to the opposite side, for which he was operated. Undoubtedly the true condition, as found by the second operation, was the angioma, which, when overdistended, caused the convulsive seizures.

There is a series of cases, however, in which only one side is filled, as shown in the illustration of Case IV. The air was injected exactly as in the other cases, but entered only the one ventricle. The shape of that ventricle is quite irregular; the line representing the optic thalamus is flattened more than normal, the height of the ventricle is greater than normal; as one studies the lateral view the anterior horn appears to be free of air, while the posterior horn appears to be enormously distended; the chiasmatal cistern is filled with air; there seems to be a defect above in the skull itself, possibly the position of a pacchionian body. This case has not come to operation yet. The *x*-rays are shown merely to illustrate this type of cases.

Hydrocephalus.—A large series of cases have been studied at the Children's Orthopedic Hospital in which the films show a progressive development of hydrocephalus. When a child shows an irritable disposition, cries out at night, shows no tendency to creep or walk, is listless and apparently subnormal, and the *x*-ray film shows a perfectly placed ventricular system, one should at once classify that case as a potential hydrocephalus. Either at this time or shortly after the appearance of convulsive seizures—first at long intervals and gradually at shorter and shorter—one concludes that he has hydrocephalus to deal with. A true hydrocephalus with complete blockage of absorption develops early and hydrocephalus with partial blocking is later in developing. The former are easily diagnosed as the head begins to develop rather early and rapidly, but the

latter are very difficult to diagnose. The little tots have a fairly well developed ossification of the bone and until the hydrocephalus reaches a certain point the sutures do not show much separation. Three months after the first picture it is not difficult to make your diagnosis. The cerebroventricular study offers considerable hope for the early diagnosis of hydrocephalus. Whether direct drainage can be secured or the technic for the removal of the plexus can be perfected sufficiently and corrective measures instituted early enough, will determine the practical value that can be expected in this class of cases.

From the above one must conclude that the cerebroventricular study seems to offer an opportunity to diagnose and possibly to relieve many conditions at an early period which, in the past, have developed into pitiful cases in later years.

CASE STUDIES

Case I.—A girl, sixteen years of age, was seen at Providence Hospital in March, 1924, under the service of Dr. George Miller. She gave the following history: At the age of nine began to have spells of dizziness, lasting but a few minutes (they appeared like a flash); two years later, at the age of eleven, had typical convulsive seizures, which lasted about ten minutes; she would void involuntarily, but never bite her tongue, the convulsion began by drawing the head to the left, then a tonic spasm over the whole body lasting a variable length of time. The convulsions occurred about once in eight or ten days. This seemed to be a typical grand mal. Between the age of twelve and fourteen she was free from these attacks. There was no history of epilepsy in the family, she was the youngest of 6 children, all enjoying perfect health except a brother, who died at eleven years of age from peritonitis; father living and well, age sixty-five, mother died at forty-two from carcinoma of the thigh. The patient had had whooping-cough, measles, and mumps in childhood. There was no history of a birth injury, she weighed between 8 and 9 pounds at birth; did not walk until about two years of age, and from the very beginning had a limp of the left foot; the left side was always smaller than the right, in school

she went through the eighth grade and stopped because of her physical deformity.

Examination revealed a well-nourished young girl. Eyes: Pupils reacted to light normally; no nystagmus; an asymmetry of the face; the left corner of her mouth drooped; there was a paresis of the muscles of the left side of the face; teeth irregular, but in good condition; a slight fulness of the thyroid; breasts well developed; chest, cardiovascular, abdomen, genito-urinary negative; left arm and leg smaller than the right; a marked diminution in size and length, practically limited to the forearm, hand, and left leg below the knee, and the foot, where there was a pes equinus, externus longus digitorum to the muscles of pronation and supination; the reflexes normal except a left Babinski; there was no vertigo; no indigestion. The cerebroventricular study on March 25th showed spinal fluid pressure 14; 30 c.c. of fluid removed in 5 c.c. amounts and 25 c.c. of air injected. This was done under local anesthesia; there was no shock. Examination of the spinal fluid showed Wassermann negative; Nonne negative; cell count 7. The ventricular shadows showed a displacement of the entire ventricular system to the right (Fig. 486); the air in the left ventricle showed a contracted ventricle entirely beyond the mid-line so that the outer tip touched the vertical line, the right ventricle showed a defect which extended from the upper horn outward over the optic thalamus to the very cortex of the brain where a wide dilatation was noted; below this area a small irregular shaped optic thalamus was depicted. A diagnosis of an angiomatous tumor was made, theoretically showing the ventricular system to the right. Consent for operation was not obtained. The objections to the diagnosis, however, in this case were the absence of a choked disk and the duration of the condition. However, the patient gradually became worse, the convulsions increased, and the mentality decreased. It was decided then that the condition was probably due to an angioma on the left side. Meanwhile Case II had been studied; the history was quite similar and the first operation had been performed and a perfectly normal brain seen at the time of operation on the opposite side.

In the light of the findings in that case when Case I was re-admitted to the Providence Hospital on August 6th it was decided to operate on the right side. The operation consisted of turning down a bone-flap over the temperoparietal region on the right side, the following notations were made on the operative slip: "1) A thin skull over the vertex. (2) Thickened dura. (3) A thick patchy arachnoid the white patches seemed to appear principally along the course of the arteries, no veins of any size

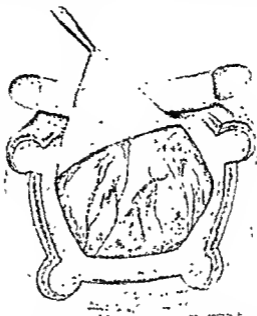


Fig 487—Case I Operative field, showing pachymeningitis; small vessels and thickened membranes covering atrophied cortex

through the arachnoid, the arachnoid elevated from the cortex and pia for a distance of $\frac{1}{2}$ cm. over the entire area to the juncture of the rolandic fissure with the sylvian fissure, one could press down on the arachnoid anywhere and cause a marked dimpling over this area, vessels seemed to course through this space, on section of the arachnoid this space was found to be filled with a transparent, jelly-like mass; the convolutions above, in front, and behind this area seemed quite normal, while the con-

volutions immediately underlying this area were white and contracted, showing an atrophic condition of the cortex" This was evidently the site of either an extensive thrombosis or embolism, or, what is more probable, the site of a birth hemorrhage, which accounted for the development on the opposite side of the body and the spells. At the time of opening the arachnoid the anesthetist's report showed the blood-pressure dropped from 124 to 94 and then to 64, while the pulse jumped

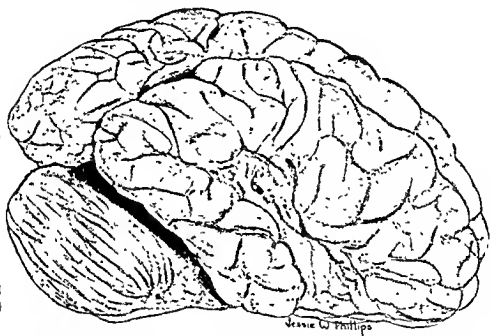


Fig. 488—Case I. Atrophied area, showing opening directly into the ventricle.

from 112 to 150. At the time there had been considerable bleeding and this change was attributed to hemorrhage, although it did not seem that there was enough hemorrhage to cause such a marked change; however it was decided to close, and the patient was given salt solution intravenously, 250 c.c. (Fig. 487).

The patient rested easily during the afternoon, lying on her back and left side; at 2 o'clock in the morning the patient turned over on the right side; the nurse noticed that she was in distress and she died within a few minutes. The autopsy revealed a shrunken right brain in which the ventricles opened

directly under the arachnoid; the opening that was made in the arachnoid at the time of operation in all probability had markedly lowered the pressure within the ventricular system. The death, in this case, coming as suddenly as it did was not unlike that reported by other observers who have used the direct ventricular

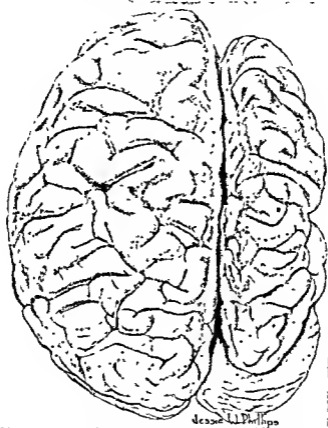


Fig 489—Case I View from above, showing relative size of the two hemispheres

puncture—in a certain position the patient is seized with a sudden collapse and dies within a few minutes (Figs 488 and 489).

The question one must consider in this case is how far is one justified in interfering with a congenital defect, obviously too much was done in this case, but there was no way of know-

ing that the sub-arachnoid space was in direct communication with the lateral ventricles. At another time this, of course, would easily be detected before operation. Does this case illustrate the cause of death where the intraventricular pressure is lowered too suddenly; in other words, does the puncture of a ventricle with a large needle so lower the ventricular pressure by constant drainage of cerebrospinal fluid that a sudden movement of the head is liable to cause some change to take place in the position of the brain, or some part thereof, which results in death. A very careful study did not reveal a hemorrhage, an embolism, or a thrombosis as the cause of death in this case. The air was used four months prior to the operation, so that it could not be attributed to the use of air. The one other cause in this case, aside from lowered intraventricular pressure, was shock due to loss of blood. It does not seem that the patient would respond and seem so clear and then suddenly die if it was due to shock.

The conclusion one must draw is that death was due to a decrease in the intraventricular pressure, which caused, on moving the head, some change to take place which resulted fatally. The other lesson to be gained from this case is the cause of these congenital defects. Did this child have a hemorrhage at the time of birth which caused the thickening of the arachnoid (leptomeningitis) and the opening of the subarachnoid space into the lateral ventricles and an atrophy of the brain on that side, as shown by the illustration. Other studies on other cases have convinced us that probably what happened was this: at the time of birth there was a hemorrhage of sufficient amount to cause this development to occur.

Case II.—A girl, four years of age, was admitted to the Orthopedic Hospital on July 8, 1924, with the following history: Mother, father, and 2 sisters living and well; full term child; normal birth; weight $7\frac{1}{2}$ pounds; breast fed; she was normal until an illness when one year of age, which began with a cold followed by convulsions; diagnosed as infantile paralysis; during the illness she awakened one morning with the right arm

and leg swollen, has had convulsions ever since, from twenty-five to thirty in a day; gradually they decreased until now they occur only at irregular intervals, always on the right side; is unconscious for a few moments and afterward falls asleep; she is lame on the right side

She was examined by Dr. D. A. Nicholson, and his report on the case is as follows. "There is a slight paresis of the muscles of the right side of the face, as shown by inability to close the right eye alone as she does the left, and the right side of the face is a trifle smaller than the left. There is a slight lisp to the speech, the tonsils are enlarged and infected; should be removed. Deltoid right side very much atrophied. There is some difficulty in elevating the right arm over the head. Grasp of the right hand is weaker than the left due to weakness of the extensor group of muscles. Some atrophy of the extensor muscles of right thigh and also of the extensors of the foot, so there is a partial foot-drop, and in walking she has to throw the leg out from the thigh and lift it high in order not to trip. It appears to me that from the history given there has been a high anterior cord lesion with possibly a cerebral lesion in addition, as shown by the involvement of the facial muscles and the speech defect. The father says she was quite sleepy at that period and the temperature continued for some time, which brings up the possibility that this was a case of encephalitis of the cerebral type in which there was considerable localized edema, and that it is the result of that edema or adhesion which is now giving rise to those one-sided convulsions. Therefore this case would probably be a proper one for an exploratory operation. I would not, of course, recommend this without first knowing the result of the spinal puncture as to the Wassermann, as to pressure, cell-count, or whether anything was shown diagnostic of a cortical lesion."

A cerebroventricular study was done on July 9th: the spinal fluid was under 30 mm. pressure; 50 c.c. of fluid removed and 50 c.c. of air injected; there was no shock following the injection of the air and x-rays were taken in the usual manner; the anteroposterior view showed the left ventricle distended to at-

least twice the size of the right; the entire ventricular system pulled or shoved to the left $\frac{1}{2}$ cm. beyond the midline; those taken twenty-four hours later showed still a considerable distention of the ventricular system; the left lateral wing seemed to be more distended than the balance of the lateral ventricle. Diagnosis: Internal hydrocephalus—probable angioma of the right side (Figs. 490 and 491).

On August 3d patient was admitted for exploratory operation. The operation the following day on the right side revealed a

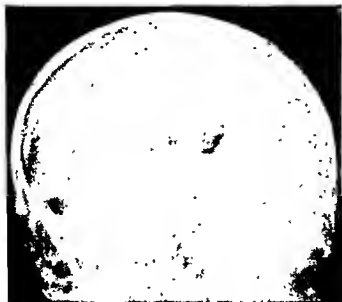


Fig. 490.—Case II. Anteroposterior film, showing displacement to the left, and left ventricle distended.

perfectly normal brain with no angiomatous mass or any condition that would suggest a shoving of the brain to the left side beyond the midline as shown in the x-rays; on August 27th the patient was operated on the left side—an angiomatous condition of the arachnoid with a lack of development of that side of the brain, similar to Case I, was found to be present; no exploratory needle was inserted into the ventricular system, as this case undoubtedly resembled Case I, in which an exploratory incision was made into the ventricle with disastrous results.

The diagnosis in this case was (1) Angioma of the arachnoid; (2) cerebral aplasia left (Fig 492).

Why did this little child's brain fail to develop on the left side; what caused the development of the angiomatous vessels in the arachnoid on this side? This can be accounted for by the presence of a hemorrhage at the time of birth, and yet the history from the mother was that the birth was normal; it was not a primipara, and there is a history of an illness coming on at

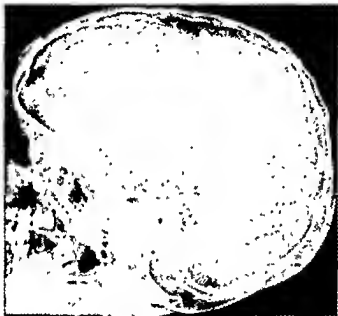


Fig 491—Case II Showing lateral view

the age of one year, can this be a case of encephalitis in which we have a localized edema followed by the development of the angiomatous vessels and atrophy of the cerebral cortex on that side, the edema may have been due to a thrombosis, but the new-formed blood-vessels would suggest more likely the presence of a hemorrhage at this time; a hemorrhagic pachymeningitis would have been followed in all probability by a thickened, new-formed membrane underlying the dura or arachnoid. I am inclined to believe that Dr Nicholson's conjecture was the

correct one, that it was an encephalitis rather than a pachymeningitis, and that the condition developed as the result of a localized edema. However, more cases of this character will have to be reported with detailed histories before any final conclusions can be drawn.

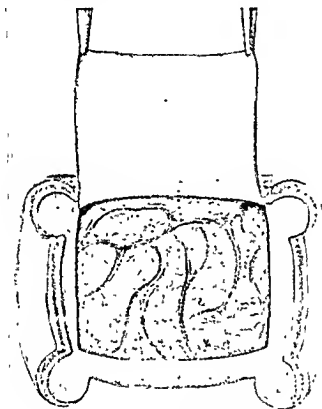


Fig. 492 —Case II. Showing angioma of the arachnoid.

Case III.—A boy, fourteen years of age, was admitted to the Orthopedic Hospital the first time in July, 1923, with the following history: A full term child; normal birth; could not swallow for about one week; weight $4\frac{3}{4}$ pounds; did not pass urine or feces at first; had hemorrhage from navel at five days when cord came off; at one and a half years had convulsions; patient has never been able to use the fingers of the left hand properly; left arm underdeveloped; at ten years of age com-

plained of left arm jerking; child is nervous and unable to apply himself at school; mother noticed slight convulsions and jerking when child was very small; attacks clonic at first, later becoming tonic on the left side, face, and neck, sometimes followed by unconsciousness, attacks always begin on the left side; does not bite his tongue; drivels, but does not froth at the mouth; mouth held open during the attacks; often vomits before or after the attack; has been to many doctors at different times, always with a diagnosis of epilepsy

Physical examination in 1923 was as follows: Well-developed, well-nourished child; head, eyes, ears, nose, and mouth normal; teeth in fair condition, throat and neck normal; tonsils have been removed, heart, chest, lungs, abdomen, and extremities, except left arm, normal, reflexes exaggerated on the left side; spine normal in appearance, skin. anus. genitalia normal, round shouldered, hands heavy, well muscled Examination by Dr. D. A. Nicholson of this child, two years previous, was as follows. "I find no lameness in the left leg, but this leg is a trifle smaller than the right, the left arm is shorter than the right and smaller, he is unable to close the left eye except when he closes the right, there is no evidence of wasting of the muscles about the left side of the face There is a history of a paralysis of this left side at birth which undoubtedly was a birth palsy, and there is a history of localized spasms of the left arm which is undoubtedly due to a cerebral lesion which was present at birth "

A diagnosis of Jacksonian epilepsy was made and he was first operated on September 12, 1923; air was injected into the spinal column after failing to locate right ventricle by direct puncture, 65 c c of fluid removed and 65 c c. of air injected in 5 c c amounts, there was some reaction at the time, patient complained of severe headache; the report of the air at that time was that the anteroposterior view shows a small amount of air in both ventricles which appear symmetric and approximately 1 inch in length by $\frac{1}{2}$ inch in width. On October 8, 1923 an exploratory craniotomy was performed by Dr. Herbert Coe over the right parietal region; a flap was raised, the dura was found to be tense; brain bulged into the dural opening; a needle

was inserted in various directions, but no cyst formation found; a solid mass seemed to be located about 1 inch below the cortex directly toward the midline, about $1\frac{1}{2}$ inches in length, no attempt made to remove the mass; the patient was discharged on January 27, 1924. The condition was temporarily improved following the operation, but later he began having more severe spells.

He was re-admitted to the hospital on July 18, 1924, and on the 19th a cerebroventricular study was made, with the fol-

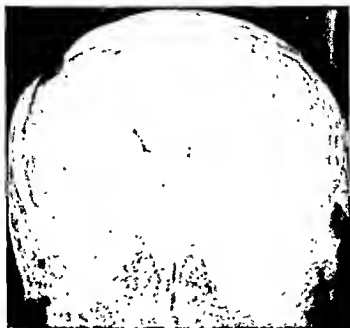

Fig. 493.—Case III. Showing defect in skull in right parietal margin, displacement of the ventricles to the right, collapse of the left ventricle, and air over left cortex.

lowing findings: 20 c.c. of fluid withdrawn from the spinal canal and 20 c.c. of air in 5 c.c. amounts injected; pressure 20 mm.; spinal fluid clear; patient suffered very little shock; the x-rays showed the entire ventricular system either drawn or shoved to the right; shape of the right ventricle normal; left ventricle collapsed (Figs. 493 and 494). A diagnosis was made of a mass, probably angioma, which shoved the ventricular system to the right, probably located on the left side. On July 28th, under

general anesthesia, an operation was performed on the left side; flap turned down exposing left dura; skull very thin and very bloody; hemorrhage could hardly be controlled by wax; dura opened over area 3 inches square, revealing angioma of the arachnoid, one large vessel along the rolandic fissure and another along the sylvian fissure, a very large aneurysm, as large as a pea, appeared in the juncture of these two; vessels normal in caliber, decompression done, interrupted sutures, subcu-

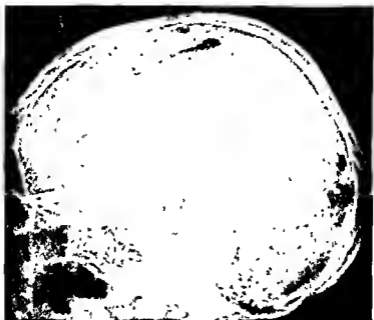


Fig 494 —Case III Showing small ventricle, chiasmatal cistern filled with air, and skull defect

taneous in skin, three rubber drains The patient made an uneventful recovery and was discharged on August 12th; told to report to Dr. H B Thompson for x-ray therapy (Fig 495)

This case presents almost identically the same picture as the previous case, a history of a weakness of one side followed by convulsions, in this respect it is also similar to Case I, in which one side of the body was undeveloped and convulsions came on at about the age of ten years, so that we have here

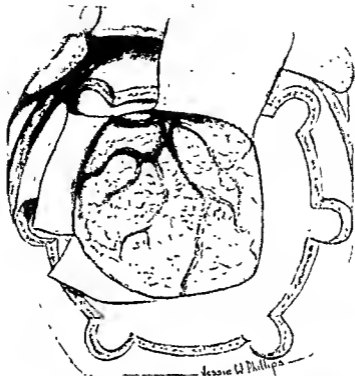


Fig. 495 —Case III Showing angioma of arachnoid.



Fig. 496.—Case IV. Showing filling of one ventricle only.

3 cases of epilepsy, 2 of which present angioma, 1 of which presents leptomeningitis with atrophy of the cerebral cortex; one a mild leptomeningitis with marked development of the vascular structures (angioma) and atrophy of the cerebral cortex, and the other a more marked development of the angiomatous condition with no apparent atrophy of the cortex. In each case the ventricular system was displaced beyond the midline. In the first

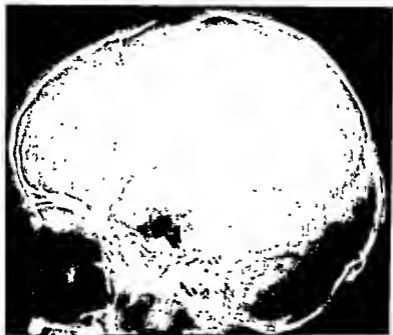


Fig. 497—Case IV. Showing defect of posterior ventricular horn, full chiasmal cistern.

2 cases the normal development of the cerebral hemisphere on one side encroached upon the space of the undeveloped hemisphere of the other side, and this gave the appearance of shoving the ventricular system to the undeveloped side; in the last case with perfect development of both sides, but with the development of an angiomatous condition of the arachnoid the mass itself shoved the ventricular system beyond the midline. The boy, Case III, did not have the marked asymmetry of the other

two; the second case, having both atrophy of the cortex and angioma, had less asymmetry than the first case, which had only the aplasia of the cerebral tissue. One might conclude from a study of these 3 cases that epilepsy beginning before ten years of age and gradually increasing, in cases where the cerebroventricular study shows an increase in pressure and a displacement of the ventricular system beyond the midline, is suggestive of (1) aplasia of the cerebral hemisphere; (2) angioma of the arachnoid. The differential diagnosis might be suggested in the asymmetry of development of the body itself. Further studies with detailed reports must be made before any of these suggestions can be verified. Birth hemorrhages in all probability play a very important part as an etiologic factor in all 3 of these cases. Just how the pathology was developed is still uncertain. These cases, furthermore, illustrate the value of the spinal approach in the use of air for cerebroventricular study

CLINIC OF DR. GEORGE M. HORTON

PROVIDENCE HOSPITAL, SEATTLE, WASHINGTON

CARCINOMA OF THE RECTUM

IN presenting this case this morning I cannot help but emphasize the importance of determining the cause of rectal bleeding before attempting any method of treatment. We can never, from our present knowledge of cancer, hope to lessen its terrifying mortality if we continue to permit so many people afflicted with a malignancy to reach the advanced stage. Most errors in diagnosis are those of omission. The failure to insert the finger in the rectum frequently robs the patient of an early diagnosis and proper treatment. The neglect of this apparently simple procedure resulted in this woman's being operated on this morning instead of several months ago.

Carcinoma of the large intestine is not an infrequent finding, and the incidence increases in frequency from the cecum to the rectum. Over 60 per cent. of intestinal carcinomas and 5.25 per cent. of all carcinomas occur in the rectum, which is, therefore, fifth in the list of primary seats of cancer.

The early diagnosis of cancer of the lower bowel is one of the important subjects in modern medicine. Even with our present knowledge of the condition and all our facilities for diagnosis, it is still a fact that a comparatively large number of patients present themselves in the stage of acute obstruction.

Cancer of the lower rectum, within reach of digital examination, should rarely be missed, yet I have seen on several occasions patients who had been treated for hemorrhoids, as in this particular case, and even subjected to hemorrhoidectomy, the operator remaining in ignorance of a palpable mass just above the internal sphincter.

The "expectant" method of diagnosis has no place in medicine, especially in those cases in which the remotest possibility of malignancy may exist. It is, to say the least, difficult to understand how a physician can treat a patient presenting a history of rectal bleeding without at least making a digital examination, and passively to conclude that such a healthy looking patient without loss of weight or evidence of cachexia, could not possibly have a cancer and, therefore, the bleeding must be due to hemorrhoids.

A nodular mass in the rectum with alternating hard and soft areas is extremely characteristic and can hardly be mistaken for anything but cancer. Pain is a symptom of late and not of early cancer. Cancer of the rectum may, unfortunately, remain free from symptoms until far advanced. In advanced cases if the lesion is low the pain is most marked in the rectum and least noticeable in the abdomen. On the other hand, if the lesion is situated high, the pain is more marked in the abdomen than in the rectum. Loss of weight is by no means a cardinal symptom in cancer of the lower bowel, and such cases may go on to complete obstruction without appreciable loss of weight.

The early stage of carcinoma of the rectum due either to the lack of symptoms or to its indefinite symptomatology, is comparatively seldom diagnosed. The lesion exists several months before the disease extends beyond the wall of the gut, and in this state there is no bleeding, no pain, and no mucus. A pronounced change in the patient's ordinary method of bowel movement extending over a period of weeks, should at least suggest to us the possibility of an early carcinoma of the rectum. Not infrequently a patient of the cancer age will state he has suddenly become constipated, or seemingly is delighted by the fact that he has within the past few months conquered a constipation that has been a continual source of worry the better part of his life. On hearing such statements the burden of proof rests upon the physician to rule out immediately the possibility of early carcinoma of the rectum. A careful digital and proctoscopic examination by one familiar with the early pathologic picture of this condition must be immediately made. If this

examination is negative, the patient should be warned to be ever watchful for the presence of blood or mucus in the stools, and on the slightest change to return for re-examination.

Carcinoma of the rectum starts first in the mucosa and is found as a small hard lump in the inner lining of the bowel. There is at this stage no surface ulceration and the growth has not involved the muscular coats. After a period of a few months the surface of the growth ulcerates and extends into the muscularis. The diagnosis should be made at this stage and the lesion not permitted to progress to a tumor capable of causing partial or complete obstruction.

Following is the history of this patient:

Mrs. M. P., age sixty-three, female, white, widow, occupation none.

Family History.—Father died at eighty-three, pneumonia; mother died at eighty-one, cerebral hemorrhage; brothers, six, 3 living and well, 2 died in infancy, 1 died at forty-nine from lung abscess. No tuberculosis, no carcinoma in grandparents' family.

Chief Complaint.—Complains chiefly of marked pressure in rectum, occasional pain, severe diarrhea, bloody stools, abdominal gas distress and cramps, with constant desire to empty bowel. Rapid loss of weight and strength in last two months. Has become markedly anemic. Has suffered from present symptoms since February of this year, symptoms becoming more aggravated in last two or three months. Further questioning discloses the fact that symptoms began October, 1923. At that time attention was attracted to pain in the rectum when in sitting position. Found relief by hot sitz-baths and by sitting on rubber cushion.

Past History.—Practically all the usual diseases of childhood. Occasional attack of tonsillitis. Typhoid at age of twenty years. About thirty-four years ago, at age of twenty-nine, she suffered from a severe colitis that lasted about eight months. Menstruation at age of fifteen normal and regular. Menopause at fifty-four. Had 5 children, normal deliveries, 1 miscarriage.

General Condition at Time of Entering Providence Hospital.

—Poorly nourished. Temperature $97\frac{3}{8}^{\circ}$ F.; height 5 feet, 8 inches; weight 150 pounds; pulse 80, regular; blood-pressure, systolic 160, diastolic 80; respiration 18, normal

Physical Findings—Heart action and sounds normal. Respiratory sounds clear and distinct over both lungs. Extraction of upper and lower teeth complete. Eyesight poor. Hearing good. No thyroid gland enlargement.

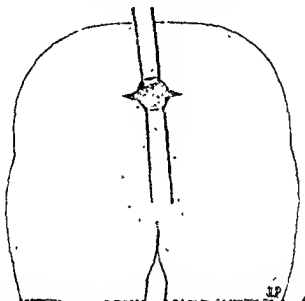


Fig 498 —At the first operation two lateral incisions are made through the external sphincter which enable the cancer to be cauterized and drains the lower segment

Digital examination of rectum disclosed an ulcerated condition about 1 inch from anus, annular in variety, and extending up the rectum about 2 inches. Bleeds very readily and causes the patient great pain during examination. No enlargement of inguinal glands. Microscopic examination of section proved it an adenocarcinoma. The patient will now be put in the lithotomy position, and in order to secure a better view of the cancerous mass in the rectum two lateral incisions will be made through the external sphincter muscle. This brings the entire

rectum into view. It also prevents the contraction of the muscle, which gives the patient suffering from cancer located near the orifice of the rectum a great deal of relief. The condition presented is shown in one of the accompanying illustrations (Fig. 498). As we are to dispense with the use of the rectum in the future, the parts will now be thoroughly cauterized with actual cautery, which will give us a cleaner field to work on when the second stage or the removal of the rectum is done.

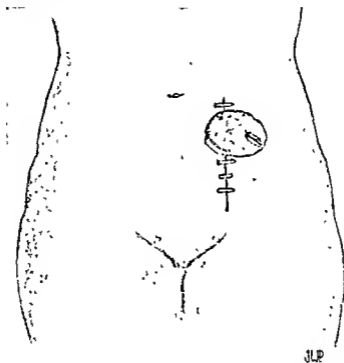


Fig 499.—Colostomy opening made in the side of the gut. This is a cleaner and more convenient method.

The patient will now be prepared for the colostomy, the ordinary method of bringing the sigmoid up and attaching it to the abdominal wall being used. Be sure to leave enough intestine protruding so it will not disappear below the skin margin when healing takes place. The distal end of the intestine as well as the approximal end are thoroughly cauterized. The distal end is invaginated the same as an appendix stump, which

is carried down into the pelvis, the peritoneum opened in the culdesac, and the intestine placed extraperitoneally. This facilitates very much the removal of the lower segment at the second operation. The accompanying illustration (Fig. 499) shows the colostomy and opening fifteen days after the first operation with deep stay sutures still remaining, the colostomy



Fig. 500—The lower segment with carcinoma ready to be removed

working perfectly, the opening in the protruding gut being at the side, which I think makes it more convenient for the patient when the bowels move, as she turns to the left side

This morning we will finish the operation started two weeks ago, at which time the colostomy was made. The patient during that time has been relieved from pain by the first stage op-

eration and has gained considerably. She will be put up in the reverse Trendelenburg position, lying on her abdomen. The usual incision will be made extending from the middle of the sacrum down to and encircling the anus. The coccyx is dissected free from surrounding tissue and excised, which gives more room for working on the upper part of the pelvis. The rectum is now dissected free and all bleeding points secured as

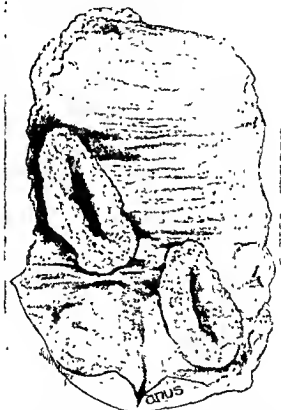


Fig. 501 —Inner surface of specimen removed.

we proceed with the operation. The dissection is continued upward until we encounter the end of the intestine which was placed extraperitoneally at the previous operation (Fig. 500). We have had a comparatively clean field to operate in because of the thorough cauterization of the cancer mass as the first step of this operation. The wound is now closed with deep silkworm-gut sutures, using rubber tubing over the sutures to prevent them cutting into the skin, as considerable tension is

usually required to approximate the raw surfaces. Cigarette drains are placed at the upper and lower angles of the wound.

The very advanced cases of carcinoma of the rectum do not, as a rule, get the attention that they are entitled to receive. They are apt to be put to one side, considered incurable, and allowed to continue their suffering. This, I think, is not quite right, as a good deal can be done for them even in very advanced stages, in the way of making them more comfortable, by giving them a colostomy and by destroying with the actual cautery as much of the malignancy as possible. Perhaps the use of radium or deep x-ray therapy would be much better, but I am very partial to the actual cautery. Too much stress cannot be laid on thorough examination of the rectum. When a patient presents himself complaining of trouble in this region, do not take for granted what the patient thinks regarding his trouble, but examine and find out for yourself, and in so doing you will not only save your patient a lot of unnecessary suffering, but perhaps keep yourself from being placed in an embarrassing position later (Fig 501).

CLINIC OF DR. THOMAS MARTIN JOYCE

UNIVERSITY OF OREGON MEDICAL SCHOOL

DIVERTICULITIS OF THE SIGMOID

Female, aged forty-eight, 3 grown children. This patient first consulted us on April 26th, and presented a most unfortunate condition. She lived in a nearby city, and for years had been troubled off and on with frequent small stools and constipation, also some abdominal pain, usually lasting for a day or so, and then subsiding after a good bowel movement. She also complained of having considerable gas.

About six weeks ago one evening she had one of these attacks, her regular family physician was away, and another doctor was called. He made the diagnosis of an acute abdomen and called in consultation. The consultant agreed with him, and decided that she undoubtedly had an acute appendix and advised immediate operation. There was some reluctance on the part of the patient and her family, as she said that she had had many such attacks before, and would rather wait for her regular physician who was out of the city and would return in a day or two. However, she was finally prevailed upon to undergo an operation, and without any rectal or vaginal examination she was taken to the hospital and her abdomen opened. The appendix was found to show very little change. In exploring the pelvis a mass was found behind the uterus in the sigmoid about as large as a fist. There was no evidence of any edema or distention of the large bowel, but this condition was thought to be malignant, and a left-sided colostomy was done and both ovaries removed.

You can imagine the state of mind of the family and the patient upon hearing this news. Massive doses of x-ray and radium

were advised, and during the next three weeks she was given massive doses of radium radiation and deep x-ray therapy.

A relative of this patient, who saw her some days after the operation, could not believe that she had a cancer. She had never had any bloody stool, and her stools, outside of being small and frequent at times, appeared otherwise to be normal. She was brought to us and the operating surgeon accompanied

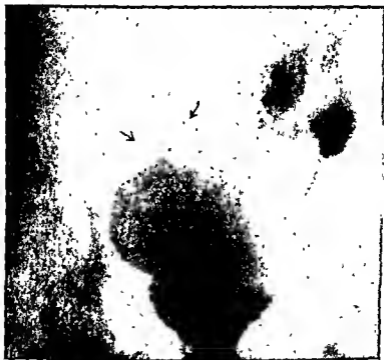


Fig 502 —Showing the diverticula of the sigmoid in Case 1.

her In going over the history of the case with him, before the patient was seen, we immediately suspected a diverticulitis. Patient was examined later. Blood-pressure was normal, and, in fact, her general examination was negative; 90 per cent. hemoglobin, Wassermann negative; urine examination practically negative. She had a left rectus colostomy, and a low midline incision scar, and considerable discoloration of the ab-

dominal wall from radiation. By plugging the upper the lower segment of the bowel protruding from the a barium enema was given with some force, and an x-ray taken which showed the rectal ampulla to be smooth, sigmoid spastic, filled poorly and rough, and there were small projections from the lumen, and while they typical, were very suggestive of diverticuli (Fig. 50). occurred at two areas situated in the sigmoid, the lower about 5 inches above the rectosigmoid junction and about the brim of the pelvis. A proctoscopic examination no evidences of any ulceration; one small polyp was removed, and found to be non-malignant.

Now, this morning, we are going to explore this abdomen through a left rectus incision and see whether not correct. I will make my incision below the umbilicus, that if necessary I can separate it and loosen it above. You see, we have many adhesions, adhesions that you do not see very frequently. They are thick, x-ray and radium and very dense. No exploratory abdomen is possible here, nor do I think it justified to be very careful to keep the small intestine protected. go down along the outside of the sigmoid until we reach the pelvis thoroughly. Here we have a small mass, it is thick, about 3 inches long, and does not show signs of inflammation. Below here is another mass, I would say, about 4½ inches of the bowel we are able to loosen and, I think, can bring down. I want to call attention that we must keep in mind as with all of these adhesions an opening is necessary, serious, leaving a fistula which it would take to close. I now have the sigmoid loose and you can see the masses, in all involving about 10 or 11 inches. I will now have to take down the colon, about 3 inches length of bowel to do an anastomosis. I will take 3 inches of good bowel below the colon, and that and use the colostomy opening as a reference. Between clamps we will divide below,

have a good blood-supply to this distal end, and you can see these two ends will come together very nicely without tension.

There are several ways of anastomosing this bowel. William J. Mayo and Balfour years ago described a method of anastomosing over a tube. I have seen two quite severe hemorrhages following the use of the tube, so do not believe that we will use it. We will use first an interrupted mattress-suture of linen tied on the inside and go clear around the lumen of the bowel. In this way there is no danger of constricting the bowel, and outside of this we will put interrupted chromic gut through the peritoneum and muscle; also make use of these tags from the sigmoid to help "cement" the suture line. Now I have this united, and I can very easily push my thumb through the lumen. We will now prepare to close this wound. I will place a long rubber tissue down on the inside and one on the outside of the anastomosis. Here we can see that the uterus is normal, both ovaries having been removed previously. Now, before we send this patient back, I am going to stretch her rectal sphincter and cut it so that it will not be possible for her to have any spasm and that gas can come away as freely as possible. Also after the first forty-eight hours she will get a large glycerin suppository daily, and after the fourth day a small oil enema daily. I think tomorrow we will also give her 3 ampules of pituitrin, given one hour apart.

Note Later.—This patient had rather a stormy convalescence for a day or two, most of her trouble being due to gas. She received an intravenous 5 per cent. glucose (500 c.c.) on the evening of the operation, and also on the following day. There was no leakage from the suture line. The drains were all removed by the seventh day, and she is now up and about and in very good condition, having normal bowel movement, and is very grateful to be rid of her colostomy. The pathologic report showed that both these tumors were segments of diverticulitis.

CHOLANGITIS WITH STONE

MALE, aged sixty-four, occupation judge. Preoperative diagnosis: Stone in the common duct. This patient first consulted us the latter part of June, 1924, complaining of loss of weight, 30 pounds in the last year, of chills and fever, with sallowness of the skin and some jaundice of the eyes off and on for the past six months. Has had a gradual loss of weight for the past year, but 15 pounds had been lost in the last four months; loss of strength also. Periodically, for the previous eight months, once or twice a week he had felt chilly for from an hour to an hour and a half, then followed by an increased temperature. Eyes and skin were somewhat jaundiced, loss of appetite. These attacks confined him to his home from one to three days. There was no pain in the abdomen, no nausea, and no vomiting. Stools were clay colored at times and the urine very dark. Several years ago he had attacks of pain under the right costal margin, but none for the past two years.

Previous History.—This man had dysentery in the Philippines in 1899, but apparently no trouble for the past fifteen years. His physical examination showed the build of a squatty individual with a slight left scoliosis and a suggestion of cachexia. He has a severe pericemental infection and absorption about the roots of nineteen teeth. There was a small abscess in the left tonsil, which was opened, and definite, foul-smelling pus was found. His heart tones were low, somewhat sclerotic. The abdomen was moderately flabby, suggestion of resistance over the gall-bladder region; no tumor palpable. Spleen was not palpable. Prostate was large and smooth. His hemoglobin was 68 per cent.; 2,700,000 red cells, 9000 whites, and a differential count about normal. Coagulation time was five and a half minutes. His urine showed a trace of indican, otherwise negative except for bile. His fasting stomach showed no free acid; test breakfast showed a total acidity of 4. An x-ray of his *gastro-*

intestinal tract was negative, except that there was a rather indefinite, elongated shadow in the region of the gall-bladder. This patient, while he showed no sugar in the urine, run a high blood-sugar curve, 116 fasting, 194 at the end of one hour and 180 at the end of an hour and a half, following the taking of approximately 100 grams of glucose. Because of the jaundice we have treated this patient with calcium chlorid according to the method of Walters. On account of his chills and fever and jaundice we advised an exploratory of the gall-bladder and ducts, so this morning that is what we intend to do. Remember, our diagnosis is a stone in the common duct with partial obstruction.

Now we make a high right rectus incision which swings over pretty close to the midline at its upper extremity. We find here many adhesions in this region. Here we have the stomach and, you can see, it is firmly attached to the under surface of the liver, as is also the duodenum. Separating this carefully, we find no evidence of any ulcer, but there is marked evidence of an old inflammatory trouble. Putting my hand down into the pelvis, he has a large prostate, some urine in the bladder. Now, coming up over the sigmoid, we find there are no masses, considerable fecal material, but no evidence of any growth in the sigmoid. The cecum is large, with an atrophied appendix. I do not believe that I will take this out. We now pack off the stomach and duodenum carefully and expose the gall-bladder and ducts, separating the duodenum very carefully, and with a gauze sponge we will push it to the left and down. Doctor now holds this with his hand and I will put a pack in on the right side. I do not find any evidence of a gall-bladder here. It is possible that this may have ruptured years ago and atrophied, but we will look a little more carefully. Below here I can feel the common duct with a large, long, hard mass. It is very difficult to make it out, but it appears to run the whole length of the duct. Again here, as you can see, is just the stump of a gall-bladder, no larger than the end of your little finger. It has almost completely atrophied. I will now split this common duct lengthwise, first catching the sides with these long, narrow forceps. As I split it, you will see bile now, rather thick and muddy,

and I will remove one portion of this stone which you can see extends well up toward the liver. Can I get this out without enlarging the opening of the duct? Here is a stone almost the whole length of the common duct. You see this stone is at least $2\frac{1}{2}$ inches long. Will now pass a probe through into the duodenum; it goes in very easily. Now this scoop. There is a great quantity of bile coming down now. I will place a Mayo-Robson tube up the hepatic duct with an opening about the junction of the left hepatic duct, resuture the common duct very carefully, and over this we will let the duodenum drop back and also pull some omentum from the colon. I will also put a cigarette drain down along the outside of the common duct to the foramen and this one large rubber tissue around both other drains. We will be very anxious to see if this drains. If this man drains bile freely he should get well. If he does not, he probably has some infection high up in the liver with obstruction, and probably will not get well. We will close this incision in the usual method with chromic catgut. Wound is now practically closed, and you see the bile is running quite freely from the tube. He will be given saline solution per rectum after returning to bed. We ordinarily use glucose, but will not in this case on account of his high blood-sugar curve. If he shows signs of shock this evening he will get some normal saline into the vein.

Note Later.—This patient got along very nicely, draining quantities of bile, and the Mayo-Robson drain remained in for two weeks. After its removal he drained a little longer than usual. I think it was undoubtedly due to the long incision made in the common duct. He left the hospital and went home, and a few days ago I heard from him that he is back on the bench and doing more work than he was able to do for the past two years.

CRETINISM AND MULTIPLE ADENOMA OF THE THYROID

GIRL, aged twenty. Received into the clinic August 4, 1924. Preoperative diagnosis: Multiple adenoma of thyroid and cretinism

This patient is about 4 feet in height; weight approximately 85 pounds. The stature was that of a child of seven or eight years of age, though more obese and with fairly well-developed breasts and hips, resembling a much older woman. The youthful appearance was lost in the facies; expression was dull and morose. There was a marked pallor about the skin; apparent edema under the eyelids and of the ankles. Posture was somewhat stooped, exaggerated by fixed position of head, much like a wry-neck. Limbs and hands were pudgy; flesh was soft, lacked the normal health and firmness. In walking the child assumed a swinging, irregular gait, as though there were poor control over the lower limbs; walking seemed difficult. It was only with the greatest amount of urging and coaxing that the child could be induced to smile. Except for a few guttural tones, and as the mother said, an occasional word to those closest to her, speech seemed to be defective and almost absent. The hearing was acute. The child seemed to be in continuous fear of approaching objects or movements. The hair was very fine and scant. The teeth were notched and irregular. Position of the neck was for the most part due to the immense multiple adenoma (Figs. 503, 504). It was because this large tumor of the neck caused pressure on the trachea and at times almost choked the child that the parents consulted a physician. For years the condition was accepted as an unknown affliction of some kind.

The mother, who is a hard working woman with a large family, had cared for and petted the child through all these twenty years. Her other children are normal, average children. The family history was negative; environment in which the child

was raised was that of an ordinary farm life. Upon several occasions doctors of the locality from which the child was brought



Fig 503 —Multiple colloid adenoma. Front view.

attempted to give her iodine or thyroid substance. The mother related that the child was unable to tolerate the medicine.



Fig 504 —Multiple colloid adenoma. Side view.

Undoubtedly, in their overzealous manner, the medicine was administered in too large doses.

Operation was advised because of mechanical obstruction

to the trachea. Laboratory work, which is usually done, was almost impossible in this case. The blood and urine examination is all that we were able to do. An attempt was made to take a metabolic rate, but it was impossible, as the patient became hysteric and fought any attempt to examine her.

We will remove this tumor in the usual manner, the child being asleep with a general ether anesthetic (it would be impossible to do any of this with local), making a collar incision. The skin, superficial fat, and platysma are turned up. You can see how these sternohyoid and sternothyroid muscles are thinned out. These we will cut high up and turn back. Here we have



Fig. 505.—Ten days after leaving hospital.

a large, multiple adenoma with degeneration. These tumor masses are soft and mushy and have the appearance very much of a fetal adenoma. We are having considerable hemorrhage here, more than we should have. As soon as this patient gets back to bed we will give her a transfusion with glucose and have a continuous flow of glucose kept up this evening and tomorrow. I do not believe that she has lost enough blood to seriously injure her. We now have removed these tumors and have left only portions of the capsule, being careful to keep away from the trachea and the region of the recurrent nerve. We have found that cases that had choking and attacks of dyspnea following operation are usually those where some injury

to the recurrent nerve has taken place. This wound will now be closed in the usual manner, suturing the muscles and placing two rubber tubes for drainage to be left in twenty-four hours; now the platysma with catgut and the skin with silkworm, subcutaneously, which we will remove in about five days. I think this child will find that she breathes much easier as soon as she wakes up.

Cases like this are difficult to distinguish between some forms of idiocy and cretinism. There are some features of this patient's condition which do not seem to be far from ordinary idiocy. Her nervousness, irritability, apathy could be accounted for by the large tumor in the neck. The patient had experienced several close calls in choking spells. She seemed to be very fearful lest anybody disturb her neck. The waxy pallor of the skin, the apparent edema of the lower lids, wrinkling of the forehead, scantiness of the hair, stubbiness and squareness of the fingers and hands, prominent abdomen, and dull, apathetic appearance are characteristic of cretinism. As a rule in cretinism the thyroid gland is not palpable. The defective speech, facial expression, guttural tones are very characteristic of idiocy. Differentiation must be accepted as a cretin, among the lowest grades of which we find mentally defective individuals and commonly, mutism. These types are found endemic in certain parts of Europe. There are over 5000 cretins in Switzerland alone, many in Austria, and the Guarneric Islands. In this country conditions of sporadic isolated cases are found, more commonly around the Great Lakes and in West Virginia. As a rule territories adjoining the sea are free from this condition. This does not hold true with the types found upon the Guarneric Islands. However, in this latter case, many scientists think that the condition is essentially dwarfism with characteristics of idiocy. Cretins are usually found in families where goiters abound, hence it is usually said that the condition is characteristic of goitrous countries. In our isolated case there are no goiters found in the family. Mutism is commonly found in 28 to 30 per cent of cretins, similar to the condition of our patient.

Prognosis as to improvement of condition is very unsatisfactory. The results of the administration of gland substance are very uncertain. In some cases results are marvelous. It is very essential that treatment be started at an early age. As a rule the administration of thyroid substance or thyroxin is given too enthusiastically. Cretins do not tolerate large doses of thyroid. It should be given in very small doses and at long intervals. Small doses of thyroxin will be given to this patient two or three times a week, not more than 0.2 of 1 mg. each time. No improvement can be hoped for, inasmuch as the child is now twenty years old and such a time has elapsed that improvement is almost impossible.

CHOLANGITIS AND CHOLECYSTITIS

THIS patient was first seen in June, 1917, and a diagnosis of chronic gall-bladder disease was made, and of a mobile cecum. She left and returned to her home and was operated elsewhere, her gall-bladder and appendix being removed, with plication of the cecum. She was very well for three years following the operation.

She then came back complaining of jaundice off and on for the past four years. It came on about the same time of year and she complained of a chilly and sickening feeling always preceding these attacks; no elevation of temperature that she knows of; complained of burning and itching. For the past five months she had been steadily but gradually losing weight and strength, and in spite of rest she had been unable to check this loss of weight or regain her strength.

At this time of examination she presents the picture of a very much emaciated woman, jaundiced, with bile in the urine; hemoglobin 42 per cent., and 3,300,000 red cells; a differential count showing no megaloblasts. This woman, on account of her jaundice, was treated with calcium chlorid, after the manner described by Walters, as we feared hemorrhage in any operative procedure with her. Her coagulation time was seven minutes four days ago, but at this time is ten minutes. She was sent in here with a diagnosis of obstruction in the common duct.

She is not a good risk, so we will do the operation as rapidly as possible. (She has been in the hospital for the past few weeks, trying to improve her condition.) The abdomen is opened through a right rectus incision, and here we find a large, thick-walled, distended gall-bladder. She evidently had an incorrect report from her previous operation, as this was supposed to have been removed. As you can see, it is enormously distended and subacutely inflamed. The common duct below here is very much thickened, but I cannot feel any stone. I think I

shall drain this gall-bladder first, as I cannot get at the common duct without either removing the gall-bladder or draining it. As we open this gall-bladder you see this thick material which looks like mud. The mucosa of the gall-bladder is entirely destroyed. I do not believe this gall-bladder would ever be any account, so I shall remove it now, being careful not to injure the common duct which appears to be filled with this same material, only thicker. The gall-bladder is removed from below up. We now tie cystic duct and artery with stitch. Now we have the common duct here. You can see it is distended and thick. Grasping the sides with these forceps, I will make a small incision into it longitudinally, and here is the same material, only it is as thick as "gumbo." Scooping this out with a small scoop, I will now try to pass a probe into the duodenum. I can pass it down to the ampulla, but it stops. We will try a smaller probe. We are unable to get this through. It is possible that she may have a stricture below and a stone. If I can't get through I will open the duodenum and try from below up. This passes down almost an inch or an inch and a half, but there is a definite obstruction there. Now, leaving the probe in the duct, I will make an incision in the duodenum here so that I can see if there is a stricture or a stone. With my finger against the end of the probe, and pushing down from above, I find that there is a thick, calloused area here, evidently an old scar, possibly ulceration from a stone having passed through. As you see, I have this dilated now, and can pass a probe and scoop from above down and from below up. This duct is pretty clear, and there is some yellow bile coming from above. We will now take a long tube, catheter, with many holes in the side, pass it from above down, leaving a generous portion through into the duodenum with many holes in the side. This I will leave in here for about three weeks. Now I am closing the opening in the duodenum with chromic gut and linen. We will close the opening in the common duct around the tube. I will state now that I am sorry I took out the gall-bladder, and should not have done so until after I had probed the common duct, as it might be useful later on in doing a cholecystenterostomy. However,

I think this tube will work all right. Placing a cigarette drain down to the closed foramen and a rubber tissue outside, we will now prepare to close this wound. I think without doubt, in addition to this obstruction, that this woman now has some biliary impairment. She undoubtedly has some hepatitis, and it is reasonable to believe that this condition of hepatitis, as described by Graham, accompanies all of these cholangitis and cholecystitis cases of the more advanced type, even to the extent of cirrhosis. We will quickly close the abdomen now and give this woman some intravenous stimulation, such as glucose, and a return flow of glucose by rectum. There is not very much bile draining from the tube here as we leave. I would say that her liability to mortality would be at least 15 or 20 per cent.

Note Later.—This patient has made a good operative recovery. The tube was left in a trifle over two weeks; jaundice is clearing up, but her anemia is not improving as fast as I would like. She has been given sodium cacodylate intravenously, special diets, and I think we will let her go home for a few months and then have her return. There has been about a 10 per cent. increase in her hemoglobin since the operation; there was no bleeding following the operation.

CARCINOMA OF THE CECUM

FEMALE, twenty-eight years old, married, has 2 children. This patient first consulted us in 1919. A diagnosis of a general asthenic and of ptosis was made at that time. She had been coming to the office off and on since then, and on October 1st of last year she came in complaining of weakness, of being tired out, palpitation of the heart, and some pain low down in the abdomen on the right side.

Her general examination showed a blood-pressure of 114. She had a greenish-yellow pallor which would suggest chlorosis. Her chest and lungs were negative; tenderness persisted over the cecum. An x-ray of her bowels showed a poorly filled, spastic cecum. A stool examination showed blood 4+ after being on a meat-free diet, and on four successive days. Wassermann was negative; gastric analysis was normal. She had a hemoglobin of 40 per cent.; 3,240,000 red cells; 5000 whites, and a normal differential count with many macrocytes and poikilocytes. The urine was negative; no blood and no pus. Our preoperative diagnosis was a tuberculous cecum. We would have to consider malignancy here also, but on account of her age and improvement in the past two weeks, as she was under observation and rest, we thought undoubtedly it was a tuberculous condition.

We will resect the cecum, and I hope for her sake that it is tuberculosis. Abdomen is now opened through a right rectus incision. The liver is negative; gall-bladder and upper abdomen appear to be negative; pelvis appears normal; the uterus is somewhat larger than usual. In the cecum we have a large, crater-like ulceration on the posterior wall which will admit the thumb. I think our preoperative diagnosis was incorrect. I believe this to be a carcinoma. We will now resect the cecum and the terminal ileum. There are many large glands which you can see here. There appears to be no involvement of the terminal

ileum, while in tuberculosis this is very common. Starting from the outside, we arise the cecum, going through the peritoneum and carefully catching all these vessels and tying them. This ulcerated area raises easily and we will take as many glands as possible. Now, with a cautery we will divide this ileum about 3 inches from the cecum, and we will take all the cecum and ascending colon and do our anastomosis into the transverse colon at about the beginning of the mesentery. I will now close the end of this transverse colon, but before doing it I will put the heavy end of a large Murphy button into the colon, as in this way I can make an end-to-side anastomosis. It can be done quickly by this method. I first saw this method of anastomosis done some years ago by Sistrunk at the Mayo Clinic. Now, we have our transverse colon closed and very close to the closure I will draw out the neck of this button through a small stab wound. We will put the other half of button into the terminal ileum, putting a purse-string around the edges and clasp button together. You see now that I have a perfect anastomosis and will carefully suture around the margin. Doctor Millett here brings in the specimen and says that it is carcinoma. I am afraid that this woman's chances are not very good. She is twenty-eight years old, recently has had 2 children, the youngest twenty months, and I have no doubt that her lymphatics have carried this beyond any measure of hope that a resection might do. However, we will use deep x-ray therapy in an effort to check any secondaries. We will close this wound without drainage, being careful not to give any fluids by rectum. She will get intravenous glucose today and tomorrow. We will also stretch her rectal sphincter so there will be no gas accumulation.

Note Six Weeks After the Operation.—This patient left the hospital in very good shape. Her hemoglobin has not shown much change, and I am afraid that before a year passes she will possibly have a recurrence of growth in liver or chest.

CLINIC OF DR. JAMES B. EAGLESON

SEATTLE GENERAL HOSPITAL

HYPERTROPHIC PYLORIC STENOSIS

DURING the past fifteen years this condition has assumed a position of great importance in the diseases of early infancy.

The honor of the first recorded diagnosis and description of the disease has long been given to an American physician, Hezekiah Beardsley, but unfortunately, this unique scientific work was lost to medical literature for over a century, until that famous delver into ancient medical lore, Sir William Osler, found it in 1903 in an old volume entitled "Cases and Observations by the Medical Society of New Haven County in the State of Connecticut," published in New Haven in 1787. Dr. Beardsley gave a complete history of the case and also notes on the postmortem findings.

More recently, however, the credit has been transferred to Dr. George Armstrong, of London, who published a clinical description and necropsy report of a case of hypertrophic pyloric stenosis in 1777. For fifty-four years nothing further is found in literature regarding the disease until Williamson reported a typical case with autopsy report, in a five weeks' old infant, in 1841. This was followed by a case reported by Dawosky in 1842. These are the only 2 cases reported during the one hundred years following Beardsley's case, until Hirschsprung reported 2 cases before the German Pediatric Society in 1888.

I do not care to go into the later historic detail since it can be easily found, but I do wish to bring the subject to you as forcibly as possible, because I believe that we medical men of the far Northwest have not given the subject due consideration, and my plea is that we must be very careful lest we are content

to bury our deceased infants with a diagnosis of inanition, acute gastritis, infantile atrophy, gastro-intestinal catarrh, marasmus, dyspepsia, or pyloric spasm, for true hypertrophic pyloric stenosis is not so rare as we were wont to believe. One hundred and twenty cases had been reported up to 1905. I operated on my first case in 1907. In 1908 Ibrahim had collected over 400 cases from the literature. In 1906 and 1907 several German physicians were reporting an increasing number of cases among their patients. So that from 0.5 per cent. reported by Heubner in 1906, Hertz reported that he had found 2.7 per cent. in children under one year in 1916. Walls was quoted as comparing it with appendicitis in early infancy by saying "that in a dispensary clinic of over 5000 patients annually, in addition to a fondling hospital and private practice, he has seen less than 5 cases of acute appendicitis in the last five years; in the same time he has had an experience of 30 cases of pyloric stenosis." Several authors have reported 2 or more cases in a single family, and others have reported cases in prematurely born infants. In recent years Downs, Strauss, Stiles, Borchardt, Still, and others have reported large numbers of operated cases from their clinics. No doubt the larger number of cases now being reported is due entirely to greater care devoted to the study of children with early stomach symptoms.

Sauer, of Chicago, has recently published a most excellent review in which he has brought the subject up to date in all its phases. His statement of the etiology is so clear that I take the liberty of quoting him. Regarding it he says, "Much is still unknown about the etiology of hypertrophic pyloric stenosis. Most authorities today agree that in every clinical case there is a certain amount of spasm. Whether this spasm is the cause of the hypertrophy or vice versa, or whether the one implies the other has been the subject of much conjecture and controversy. We know that the pylorus can frequently be palpated weeks after the vomiting ceases, that hypertrophy and visible gastric peristalsis may persist for months without vomiting, and that typical vomiting and hyperperistalsis may exist for weeks without hypertrophy.

"Starting with the premise that hypertrophy is always present, three possible theories as to etiology present themselves.

1. "Hirschsprung's congenital hypertrophy theory considers the condition an organic anomaly, *i. e.*, the reduction of the pyloric lumen is caused by the primary muscular hypertrophy. To substantiate this view are mentioned the early presence of hypertrophy—for example, in the seven months' fetus described by Dent—and the increasing number of cases operated on during the first few days after birth. Its adherents explain the cases which are free from symptoms the first few weeks until suddenly the typical vomiting with its chain of symptoms appears on the ground that the tumor causes only a slight obstruction to the lumen, and the irritability of the stomach comes on later than in those cases where the anatomic obstruction is more marked. They attempt to explain the change in consistency of palpable tumors and the not infrequent sudden cessation of vomiting in spite of a persistent tumor and visible gastric waves on the basis of an increase of the muscularis of the entire stomach wall.

2. "According to the spasm theory, the primary disturbance is not an anatomic anomaly, but a fetal spasm of the pylorus which produces a functional narrowing of the lumen and a subsequent hypertrophy of the muscle layer. Thomson maintains that the spasm may occur during intra-uterine life because of swallowed liquor amnii or other irritant. Pfaundler's original conception was that only a spasm of the pylorus exists and that the apparent hypertrophy is really a spastic contracture of the normal pyloric musculature. He reiterates that a thickening of the wall of the pyloric canal, a projection of the pylorus into the duodenum, and a decrease of the lumen by folds of mucosa are found in every infantile pylorus. A palpable tumor, according to this concept, is the spastic, contracted pylorus, which when relaxed, is not palpable. In severe cases, especially during the height of the disease, it is always, or nearly always, hard and palpable; during convalescence, it is more frequently soft. Heubner assumes a primary, congenital gastrospasm in predisposed individuals. This hypersensitive state of the gastric wall

may be present for some weeks after birth without producing symptoms

"The main objections to this primary spasm theory are: (a) If a spasm of the pylorus is primary, hypertrophy of the stomach, at least of the pyloric antrum rather than of the pylorus, should occur (b) Severe cases of pylorospasm have come to autopsy months after the onset of symptoms without compensatory hypertrophy of the pyloric musculature (c) Bernheim and others failed to find an increase in mitotic figures of the pyloric muscle-cell nuclei, such as should be found in compensatory hypertrophy (d) Spasm fails to explain the histologic evidence of an actual hypertrophy of the muscle layer. (e) This theory fails to account for the fact that the pylorus remains hypertrophied months after spontaneous recovery.

3. "The theory promulgated by Nordgen in 1902 and expanded by Schmidt assumes the hypertrophy to be primary and the spasm secondary. If the muscularis is hypertrophied, the mucosa is thrown into more and deeper folds, whereby the pyloric lumen is reduced. When such a muscularis relaxes, these mucosal folds are only partly obliterated and the passage of food through the pyloric canal is more or less obstructed. The hypertrophy alone need not cause symptoms, but under such circumstances an otherwise insignificant irritation may cause spastic contractions, and these produce the characteristic vomiting with its accompanying symptoms. As long as these spastic contractures continue, the vomiting and weight loss persist. The vast majority of cases do not progress to a complete occlusion of the lumen, and the presence of typical tumors, months after vomiting has ceased, may be interpreted as proof that the hypertrophy does not necessarily increase with age. The course of the disease is dependent, therefore, on the degree and continuity of the spasm of the hypertrophied muscularis. When the spasm is not continuous, the symptoms lessen in severity, but the peristaltic waves may continue, partly as a consequence of the hypertrophied stomach musculature, partly as a consequence of a partial obstruction remaining at the pylorus. The sponsors of this theory, however, fail to explain the sudden

occurrence of the spasm and the frequently spontaneous cessation of symptoms. Strauss has repeatedly observed, under the fluoroscope, and at operation, independent, rhythmic, snake-like contractions of the pylorus. These, he thinks, produce hypertrophy on the same basis that any muscle that is in constant motion is hypertrophied. The tumor grows, but the size does not indicate the amount of obstruction present. He has also observed that the longer that symptoms have persisted, the greater the compensatory hypertrophy of the pyloric antrum.

"In spite of the fact that macroscopic inspection of the pylorus, accurate measurements of the diameter of the muscularis, and cytologic study of the muscle cells and their nuclei tend to show the existence of hypertrophy in stenosis cases, a number of investigators question the existence of an actual increase in the muscle layer. Thus Pfaundler takes the stand that the pylorus in these cases is merely in a state of spasm, and Haas believes 'hypertrophic pyloric stenosis to be an advanced degree of pylorospasm.' Mohr questions the validity of microscopic measurements in determining pyloric hypertrophy. The marked variations given by Hertz and others for the thickness of the pyloric muscularis not only of stenosis cases but also for the normal systolic pylorus make him ask: 'When is a pylorus hypertrophied?' He reiterates that a micron is a very small unit of measure, that it is difficult to section specimens in exactly the same plane, and that it is almost impossible to obtain two stomachs in the same stage of contraction. Pfaundler raises the objection that most of the microscopic studies have been based on material hardened in formalin, and Aschoff has demonstrated the marked influence of fixing fluids on the contraction of the pylorus. This suggested to Sauer another line of attack in an attempt to prove definitely the existence of hypertrophy in pyloric stenosis. Wax models were prepared of the muscularis of the pylori of two male infants of approximately the same birth weight, and practically the same age at the time of death. The wax model of the normal muscularis weighed 3000 gm.; that of the stenosis weighed 6050 gm., a conclusive demonstration that an appreciable hypertrophy exists.

"Although Wernstedt maintains that we have no proof that the hypertrophy is congenital, most authorities agree that a condition which almost invariably makes its appearance within the first eight weeks of life (usually within the first three), and not infrequently in premature infants, in twins, or in several members of a family, must be congenital. It is quite unlikely that the degree of hypertrophy found at operation during the first few days of life could have developed in such a short time. The persistence of hypertrophy months after spontaneous recovery or years after a posterior gastro-enterostomy operation proves that the hypertrophy is not dependent on spasm. The clinical picture, on the other hand, is dependent on spasm whether accompanied by hypertrophy or not. The absence of hypertrophy in older children, years after spontaneous recovery, is due to an increase of the other tissues and the physiologic disappearance of the infantile type of pyloric canal.

"Physiologic pathology teaches that compensatory hypertrophy is the result of overwork, frequently brought about by an obstruction at some point beyond the site of the hypertrophy. The increase of the muscularis of the pyloric canal, if due to compensatory hypertrophy, must result from difficulties encountered in the closure mechanism, as the increase usually involves the circular layer. The studies of Heusch tend to show that in some cases the hypertrophy of the pylorus is the result of overwork due to difficulty in pyloric function caused by bands, etc., in the immediate vicinity of the pylorus. He takes it for granted that in these cases the hypertrophy was caused by obstruction. Strauss found no such bands or mechanical obstruction in the 365 cases operated on by him, and the great majority of pathologic studies by other observers fail to show such obstruction in the immediate vicinity of the hypertrophied pylorus.

"In his study on hypertrophy of the muscularis Sauer made the interesting observations that the lumen of the control model was funnel shaped; that of the stenosis model somewhat resembled the letter X. The plane of the lumen of the control model was horizontal; that of the stenosis case was horizontal,

vertical, horizontal. He points out that further study of these differences might shed light on the etiology of the disease.

"The time and mode of onset of the clinical symptoms, the course of the disease, and the not infrequent sudden cessation of vomiting make the spasm element the decisive factor in hypertrophic pyloric stenosis. The numerous autopsies, performed on infants who died of other causes months after the symptoms of stenosis had spontaneously disappeared, showed a persistent hypertrophy—proof that hypertrophy alone need not elicit symptoms. The presence of gastric hyperperistalsis and its persistence for weeks after vomiting has ceased need not be the result of compensatory hypertrophy. Heubner believes the spasm to have its seat not only in the pylorus, but in the entire stomach wall. He believes this 'gastrospasm' to occur in predisposed infants whose entire gastric muscularis is hypertrophied."

One case was observed by Egelson and Gray some years ago in which all the symptoms pointed to a typical case, but operation was refused by the parents of the child. On careful feeding with thick foods, stomach lavage and olive oil instilled into the stomach, the symptoms improved, the child gained in weight, and apparently was progressing quite well until ten months of age, when it developed acute vomiting attacks, accompanied by convulsions, and died in two days. The autopsy revealed an acute inflammation and narrowing of the lumen in the upper sigmoid. The stomach showed a typical hypertrophic pyloric tumor. When the stomach was removed and the cardia ligated, it was found impossible to force a drop of the thin fluid contents through the pylorus. In addition to the hypertrophy of the muscularis, the folds of the mucosa were so swollen as to completely block the pyloric canal.

The symptoms of pyloric stenosis are usually quite characteristic. They are usually well developed male infants (about 75 per cent.), the majority having been breast fed prior to the onset of the symptoms. They usually show no signs of any stomach trouble until the end of the first or during the second week.

Sauer gives 448 collected cases, in which the exact time of onset of the vomiting was recorded, in which it was found to be as follows

	Cases.
In the first week of life	105
In the second week of life	103
In the third week of life	125
In the fourth week of life	58
In the fifth week of life	23
In the sixth week of life	18
In the seventh week of life	7
In the eighth week of life	5
Later	4

"This shows that over three-fourths of these cases developed symptoms within the first three weeks of life, and in less than 1 per cent. did the disease begin after the second month"

The vomiting begins without any apparent cause, and gradually becomes more frequent and severe until it becomes projectile in character. The milder type of cases, which are amenable to medical treatment, usually clear up in two or three weeks and then progress more slowly. The severe types in which the amount of food passing through the pyloric canal is very small lose weight rapidly and the child soon becomes much exhausted and in a severe state of emaciation, which, if permitted to progress, soon gives them the appearance of the "Indian famine babies," and death follows the exhaustion in the course of a few weeks, seldom longer than three months.

When the child has lost one-fourth of its birth weight the condition is looked upon as quite critical, and Quest's statistics would indicate that a weight loss of more than 34 per cent. of the birth weight is incompatible with life. A number of observers have, however, reported cases of recovery when the loss has exceeded this percentage, one even to 50 per cent. of the birth weight.

The vomiting is the most pronounced symptom, at first quite frequent, soon becoming projectile, and as the stomach becomes dilated the frequency diminishes, but the amount thrown off increases with the length of the interval. In the later stages the child may not vomit more than two or three times per day.

McKechnie says that "In a given well-developed case, if careful record is taken of the amounts of liquids given, and care is taken to catch what is vomited, and an allowance made for what will be absorbed by the wipes and towels, it will be found that the vomitus about equals the ingesta. The vomiting is apparently not accompanied by nausea, as there is no pallor or sweating, and after the stomach is emptied the child looks as bright as before, and is quite ready to feed again."

The vomitus contains only the food taken, mixed with mucus, and does not contain bile, but may contain slight streaks of blood from abrasions of the mucosa. As the vomiting increases the stools become smaller, and finally are composed almost entirely of mucus and bile.

The next symptom in importance is the "peristaltic waves" which are caused by rhythmic contractions of the stomach wall, which usually appear a few days after the vomiting becomes severe. They usually appear after a feeding, or can nearly always be developed by having the child suck a nipple with water in the bottle. They have a definite course, begin at the left costal arch, cross the epigastrium diagonally, and disappear in the right hypochondrium. They come on at fairly short intervals, and frequently two waves may be seen at once. In rare cases the peristaltic waves may be slight or periodic, or even wholly absent.

The next important symptom is the rapid emaciation, which, of course, depends upon the degree of obstruction that has been produced by the pyloric tumor. This tumor can frequently be palpated by delicate touch in the region of the pylorus. Some observers claim that they are always able to demonstrate the presence of the tumor, but this depends largely upon the skill of the examiner and the extent of the emaciation.

A big liver may so overhang the pylorus as to shield it, or if the infant is crying, the rigid muscles may hide it. It usually lies to the right of the vertebral column, about $1\frac{1}{2}$ to 2 inches above the navel. As it is freely movable, it recedes before the examining finger and can be gently touched and felt as a small round body. It feels like a small hard gland, and at the opera-

tion one is surprised to find it much larger than palpation has suggested

When the above symptoms are well marked the diagnosis is usually easily made, the main difficulty is to distinguish between pylorospasm and stenosis. When there is any doubt in this regard we should not hesitate to resort to a fluoroscopic examination. Strauss goes so far as to state that this is the most important means of making an examination. He further believes that it not only shows whether or not the case is one of pyloric stenosis, but that it decides for us immediately whether the patient should receive medical or surgical treatment. He makes a routine part of the examination as follows: "A small amount of bismuth is added to the mother's milk, and the child is placed under a horizontal fluoroscope. It is allowed to nurse the bottle while we watch the passage of bismuth-milk through the esophagus. If the child is permitted to lie flat on its back the bismuth-milk gathers on the left side of the vertebræ as a large round mass and will lie there indefinitely. If the baby is rotated to the right side, almost on its abdomen, we will see the bismuth gradually gravitate toward the pyloric end of the stomach and peristaltic waves are immediately visible in the pyloric antrum and pylorus. A small amount of bismuth now squirts through, and the pylorus clamps down tightly. Immediately peculiar and characteristic, rhythmic, snake-like contractions can be seen in the pylorus, which are independent of the rest of the stomach. This, he claims, is absolutely pathognomonic.

He has standardized the emptying time, so that any case in which one-half or more of the bismuth-milk remains at the end of four hours is recognized as a case of pyloric stenosis, and surgical treatment is indicated. Where 80 per cent. or more of the bismuth-milk has passed through the pylorus at the end of four hours the case can, as a rule, be cured medically.

In his cases diagnosed by this method he has treated 75 per cent. surgically, and 25 per cent. medically. The latter all recovered completely on breast milk or thick cereal feedings.

Sauer has recently collected 497 cases treated medically with an average of 89 per cent. mortality, and 761 cases treated

surgically with an average of 12 per cent. mortality. He states that the "success in the treatment of this disease depends primarily upon: 1, The condition of the patient at the time that proper treatment is instituted. 2, The facilities for the proper nursing care and isolation of the patient. 3, The degree of obstruction at the pylorus. 4, The skill of the physician and surgeon."

The fact that many cases are treated medically until almost moribund before surgery is resorted to probably accounts for the higher mortality in the operative treatment.

Gastro-enterostomy was the operation of choice until 1911, with a mortality of 49 per cent. in 135 cases. Since then the Fredet-Rammstedt operation, on account of its simplicity, has practically superseded it.

In performing this operation great care should be taken to preserve the integrity of the mucosa. The incision into the tumor should go only part way through the tumor. The rest of the thickness should be opened by blunt dissection or tearing through by taking hold of both edges of the incision and separating them. Carefully spreading it with artery forceps is a very good method.

There is seldom any difficulty from hemorrhage, which can usually be easily checked by a mattress-suture or stitching a bit of tissue over it.

The mucosa should be well freed by blunt dissection in order that the folds may be released and it comes well up between the cut edges of the tumor. Some operators recommend covering this with a layer of omentum, but this seems to add little, if any, to the results. The mortality by this operation averages about 15 per cent.

Still in 1923 reported 28 cases operated on by the Rammstedt method, with a mortality of 40 per cent., so he abandoned it for forcible dilatation. He reported 46 cases treated by this method, with but one death.

Strauss, in 1912 to 1915, developed his operation by experimentation, on account of the high mortality in gastro-enterostomy and because the Rammstedt operation did not always

tion one is surprised to find it much larger than palpation has suggested.

When the above symptoms are well marked the diagnosis is usually easily made, the main difficulty is to distinguish between pylorospasm and stenosis. When there is any doubt in this regard we should not hesitate to resort to a fluoroscopic examination. Strauss goes so far as to state that this is the most important means of making an examination. He further believes that it not only shows whether or not the case is one of pyloric stenosis, but that it decides for us immediately whether the patient should receive medical or surgical treatment. He makes a routine part of the examination as follows: "A small amount of bismuth is added to the mother's milk, and the child is placed under a horizontal fluoroscope. It is allowed to nurse the bottle while we watch the passage of bismuth-milk through the esophagus. If the child is permitted to lie flat on its back the bismuth-milk gathers on the left side of the vertebræ as a large round mass and will lie there indefinitely. If the baby is rotated to the right side, almost on its abdomen, we will see the bismuth gradually gravitate toward the pyloric end of the stomach and peristaltic waves are immediately visible in the pyloric antrum and pylorus. A small amount of bismuth now squirts through, and the pylorus clamps down tightly. Immediately peculiar and characteristic, rhythmic, snake-like contractions can be seen in the pylorus, which are independent of the rest of the stomach. This, he claims, is absolutely pathognomonic.

He has standardized the emptying time, so that any case in which one-half or more of the bismuth-milk remains at the end of four hours is recognized as a case of pyloric stenosis, and surgical treatment is indicated. Where 80 per cent or more of the bismuth-milk has passed through the pylorus at the end of four hours the case can, as a rule, be cured medically.

In his cases diagnosed by this method he has treated 75 per cent. surgically, and 25 per cent. medically. The latter all recovered completely on breast milk or thick cereal feedings.

Sauer has recently collected 497 cases treated medically with an average of 8.9 per cent mortality, and 761 cases treated

give relief, especially in older infants where the tumor is often large.

He devised a modification of the Rammstedt operation. In reality a new operation which is a form of pyloroplasty having for its object the transformation of the pathologically deformed pylorus into one of more normal type. His method is that of making the longitudinal incision practically in the same manner as the Rammstedt, but he shells out the mucosa, loosening it down from both edges of the incision in the muscle, until it is

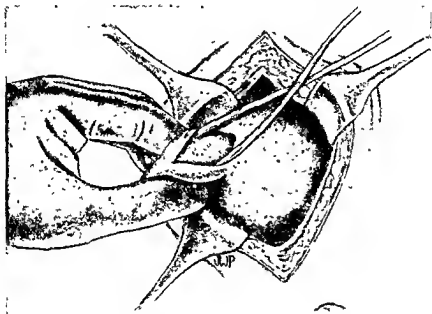


Fig. 508.—Bringing mucosa up between edges of muscle (Rammstedt.)

entirely freed except a narrow portion on the posterior side. This permits the mucous folds to expand and gives the normal size to the mucous pyloric canal. He then retracts the muscular tumor at one side of the incision, and, with a knife, splits it from within out to near the cut edge. This thin layer of muscular tissue is brought forward and carried over the mucosa to the opposite edge of the incised muscle to which it is attached by a few silk sutures. The mucous pyloric tube is thus not only enlarged, but is entirely enclosed by the muscle again. (See

Figs 509-511) He then covers the raw muscular surface by a bit of omentum.

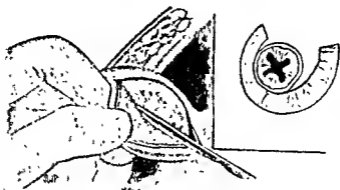


Fig 509 —Shelled out mucosa (Strauss)

His mortality by this operation has been but slightly over 3 per cent as against an average of about 15 per cent. by the Rammstedt method

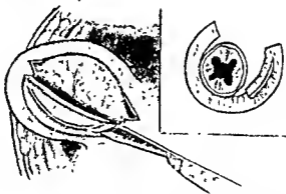


Fig. 510 —Splitting muscle tumor with knife. (Strauss)

The end-results in the successful operations by any of the methods appear equally good.

In my own early cases of gastro-enterostomy the children soon gained in weight, and have grown as rapidly as normal

children. Three boys are now seventeen, sixteen, and fifteen years of age, and are strong vigorous young men. Several of them have been fluoroscoped and the food was still passing through the stoma, and none through the pylorus. I have had no mortality to date either in the gastro-enterostomies or Rammstedt operations.

Lewis and others have found that the pyloric tumor remained unchanged after the gastro-enterostomy, while Wollstein reports that the healing after the Rammstedt operation occurred through the connective-tissue cells of the serosa and submucosa. The unstriped muscle cells took no part in the process. Within nine

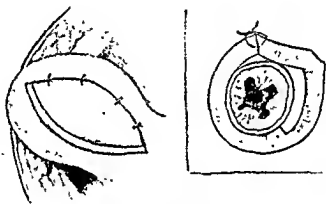


Fig 511—Muscle flaps sutured to opposite side, covering freed mucosa.
(Strauss)

days the wound in the pylorus was healed by a thin layer of connective-tissue cells. The stomach has returned to its normal size within a month, and the gap between the cut ends of the muscle coat had practically disappeared in six weeks, because of contracture of the connective-tissue scar. At the end of two years only a thin line of connective-tissue fibers separated these two muscle ends, and the stomach was quite normal. These deductions were made on autopsies in cases that lived from a few hours to two years after operation.

The case which we wish to report with this article is a baby girl, six weeks of age. Mother and father healthy. Mother had



Fig. 514—Contraction near middle of stomach



Fig 515—End of wave



Fig. 516 —Amount of bismuth meal passed pylorus in three hours



Fig. 517.—The Gray board with and without pads.

ceased in a few days. The babe was sent home on the fifteenth day, with wound nicely healed, and having gained 1 pound in weight since the operation.

Much progress has been made in the past ten years in lowering the mortality in the treatment of this disease, and still



Fig 518—Baby strapped to Gray board

greater results will be obtained when the medical man ceases to treat his surgically diagnosed cases too long, and the surgeon becomes more gentle in handling the extremely delicate tissues with which he must deal in operating upon these emaciated children.

